

09.11.2023

ÓLI HILMAR

# SKOÐUN NÝBURA

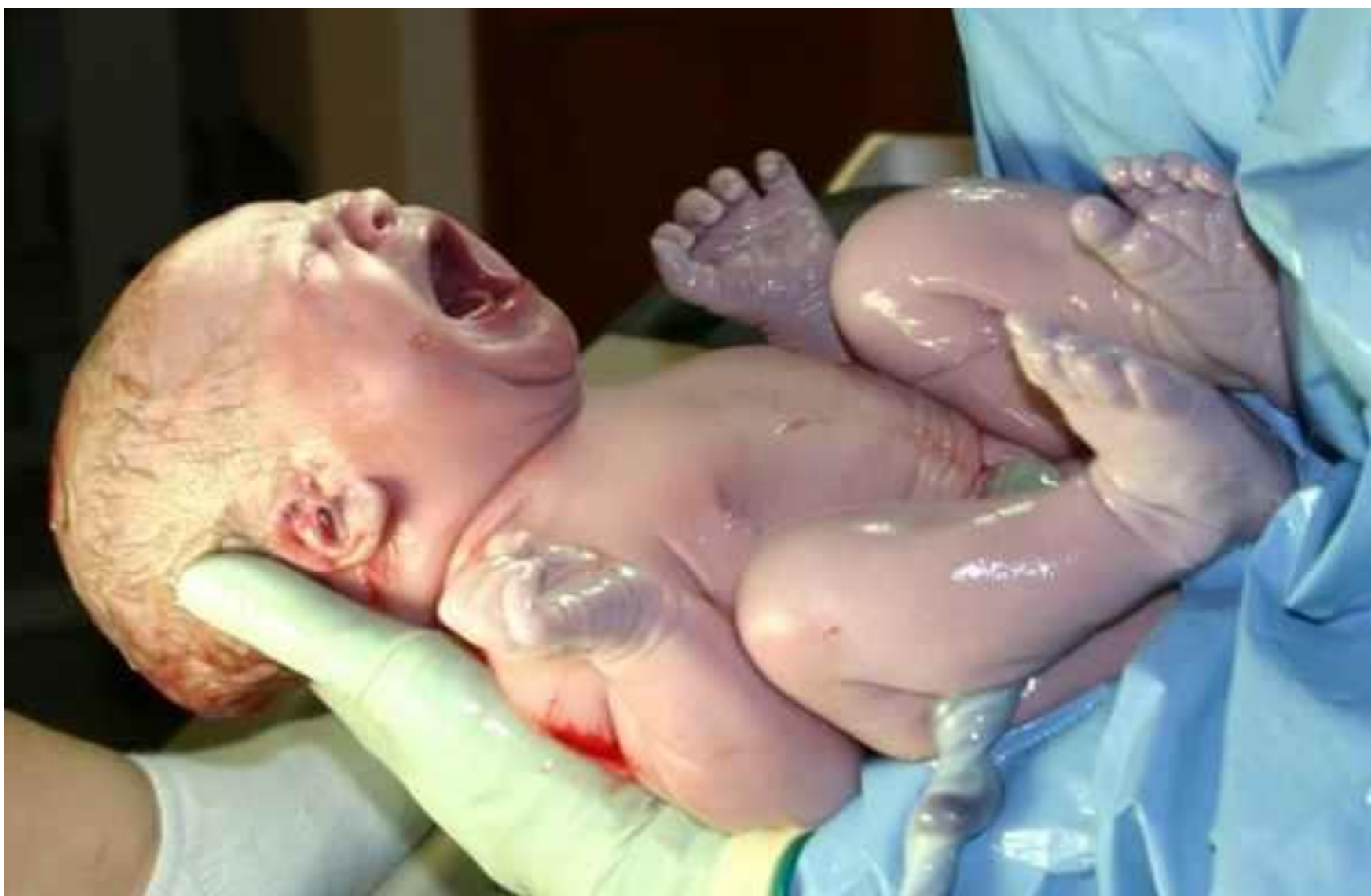# SKOÐUN NÝBURA

- Þyngd, lengd, höfuðummál
  - Skrá í vaxtarkúrfuna (aftan á fæðingarblaðinu)
- Allir nýburar eru skoðaðir af barnalækni fyrir heimferð
  - Einkum verið að leita að fæðingagöllum og merki um fæðingaáverka
- Fimm daga skoðun
  - Mikilvægt að hlusta eftir nýtilkomnum hjartaóhljóðum og finna femoral púlsa
- Önnur skimun:
  - POX
  - Heyrnarmæling
  - PKU

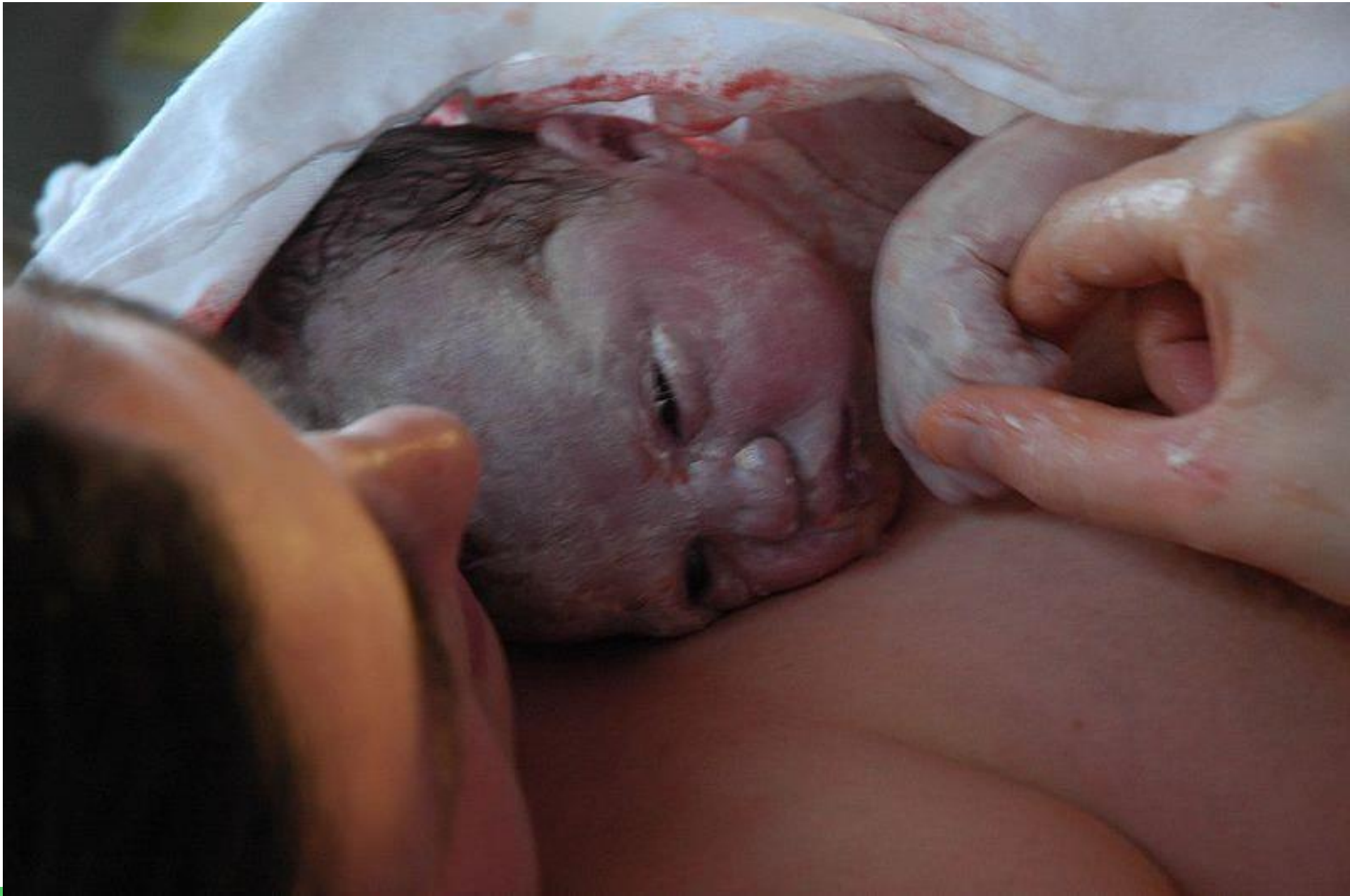**HVAR Á ÉG AÐ  
BYRJA?**

# SKOÐUN NÝBURA

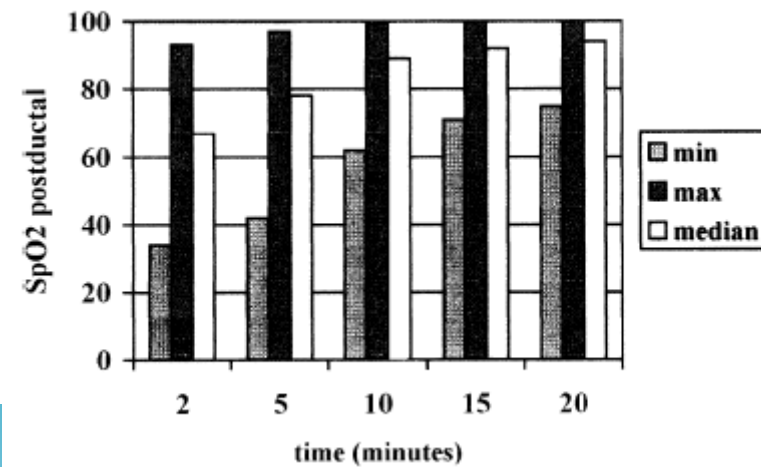
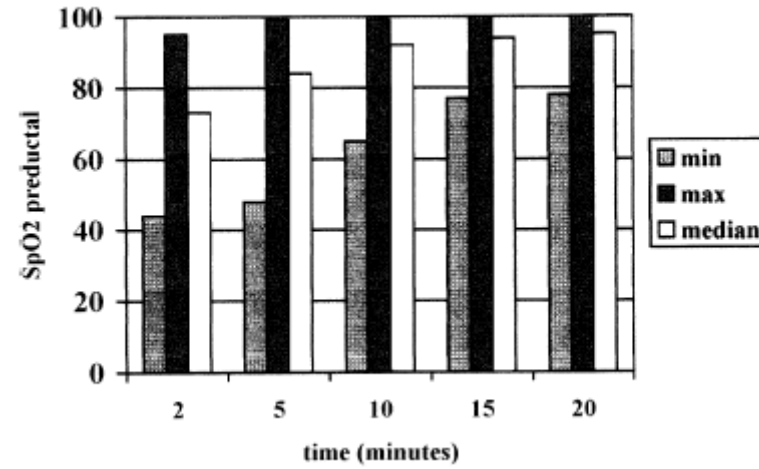
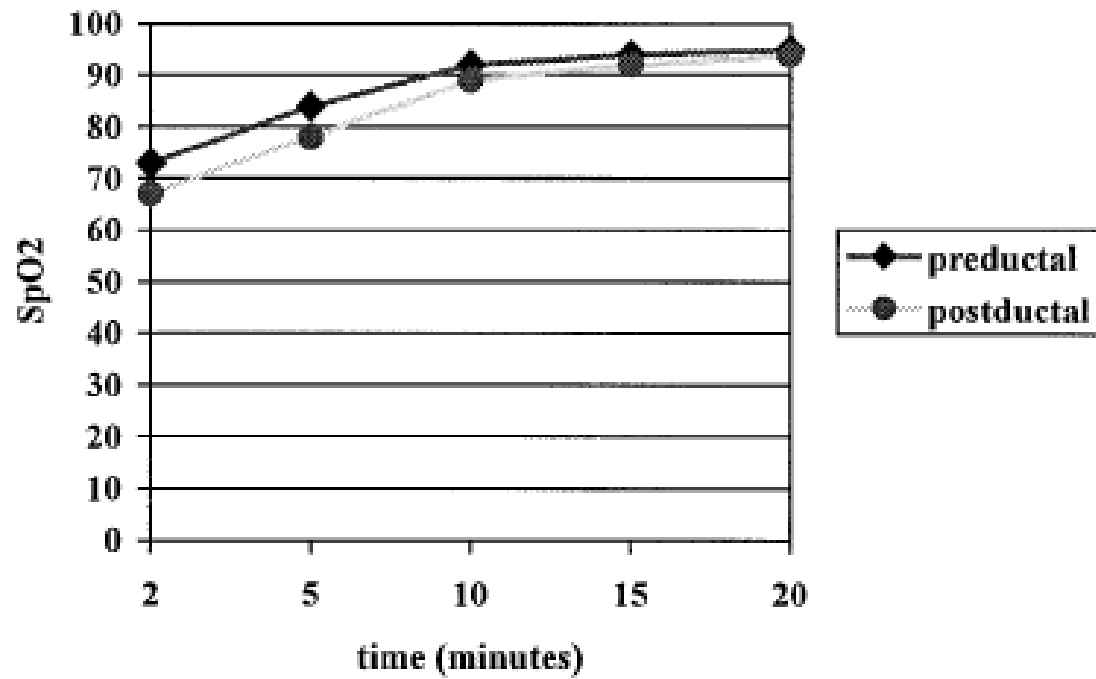
- Almenn  
  - Litarháttur (Acrocyanosis vs Central cyanosis)
  - Blóðflæði til húðar
  - Vöðvatonus / Hreyfingar
  - Moro reflex / Grip reflex
  - Ytri fæðingagallar
  - Þroskamat

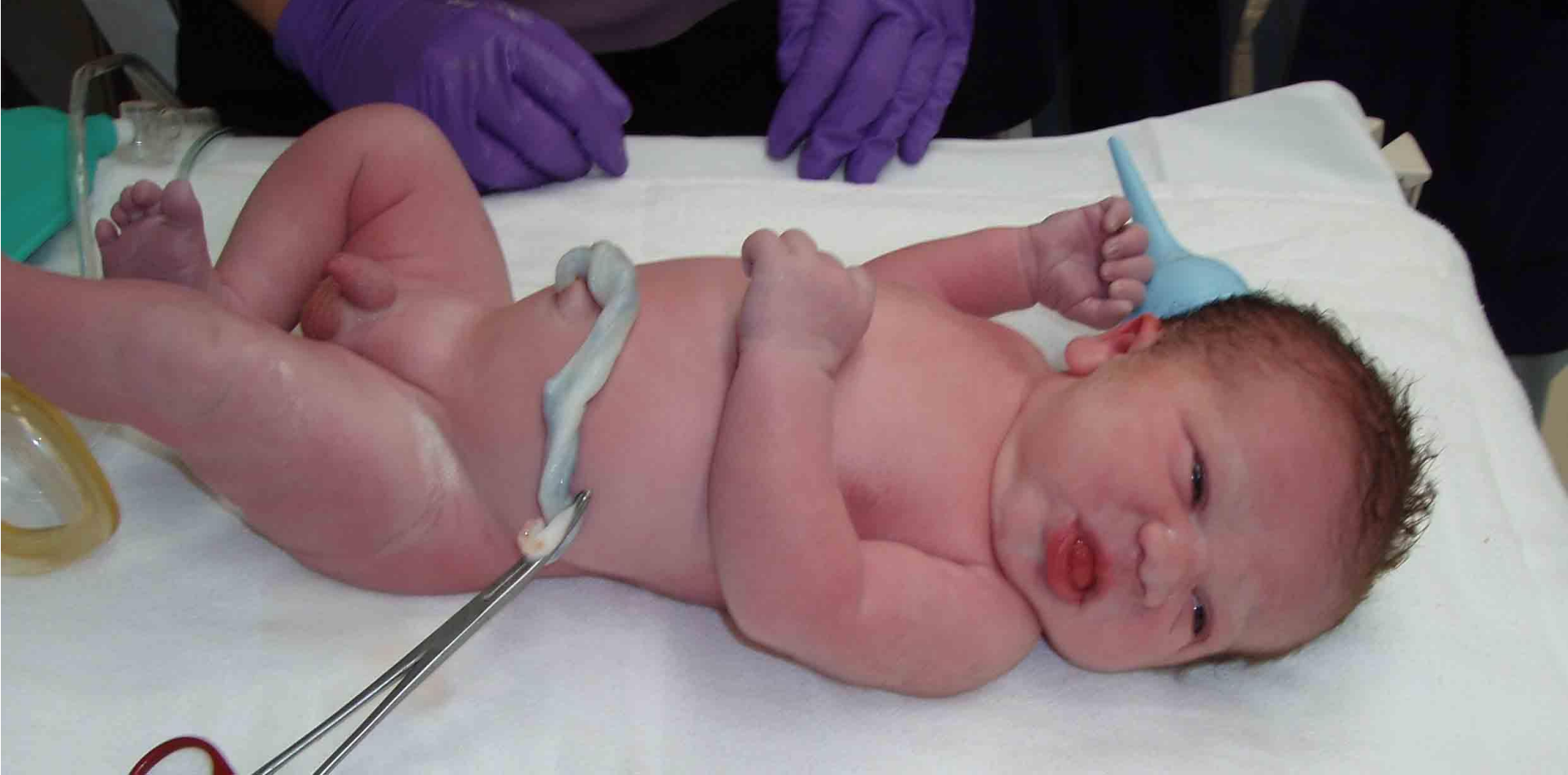





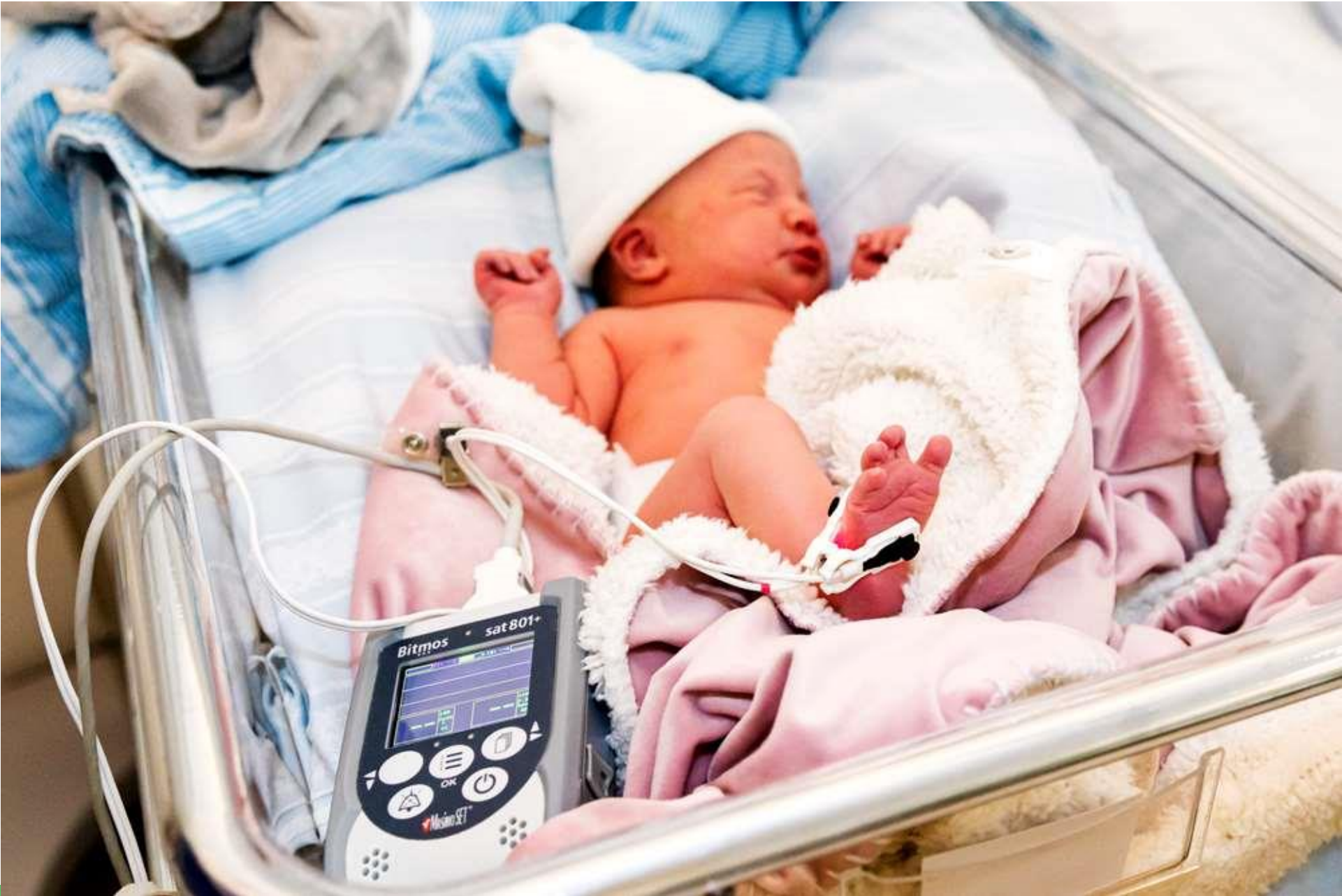# Súrefnismettun fyrst eftir fæðingu

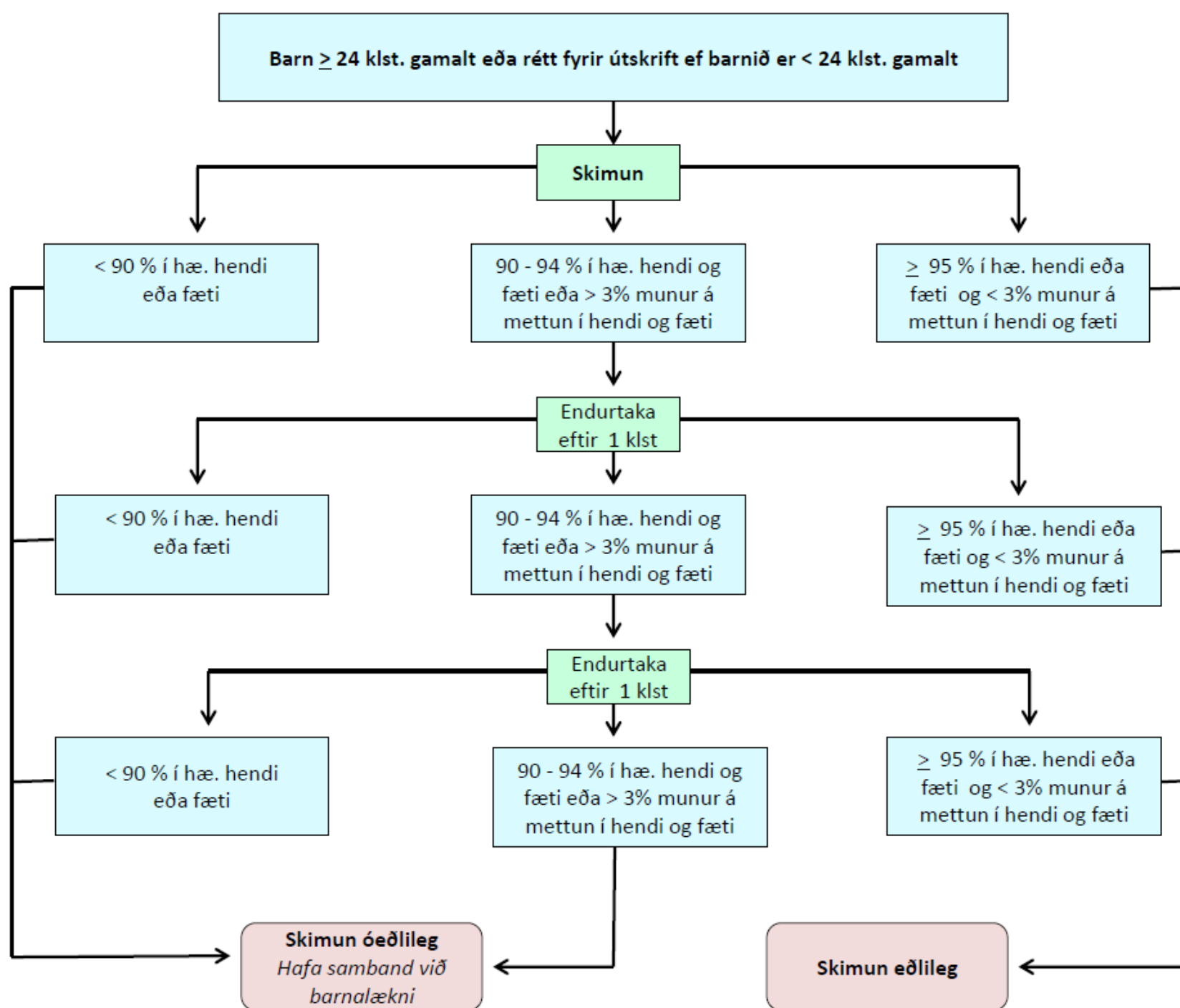




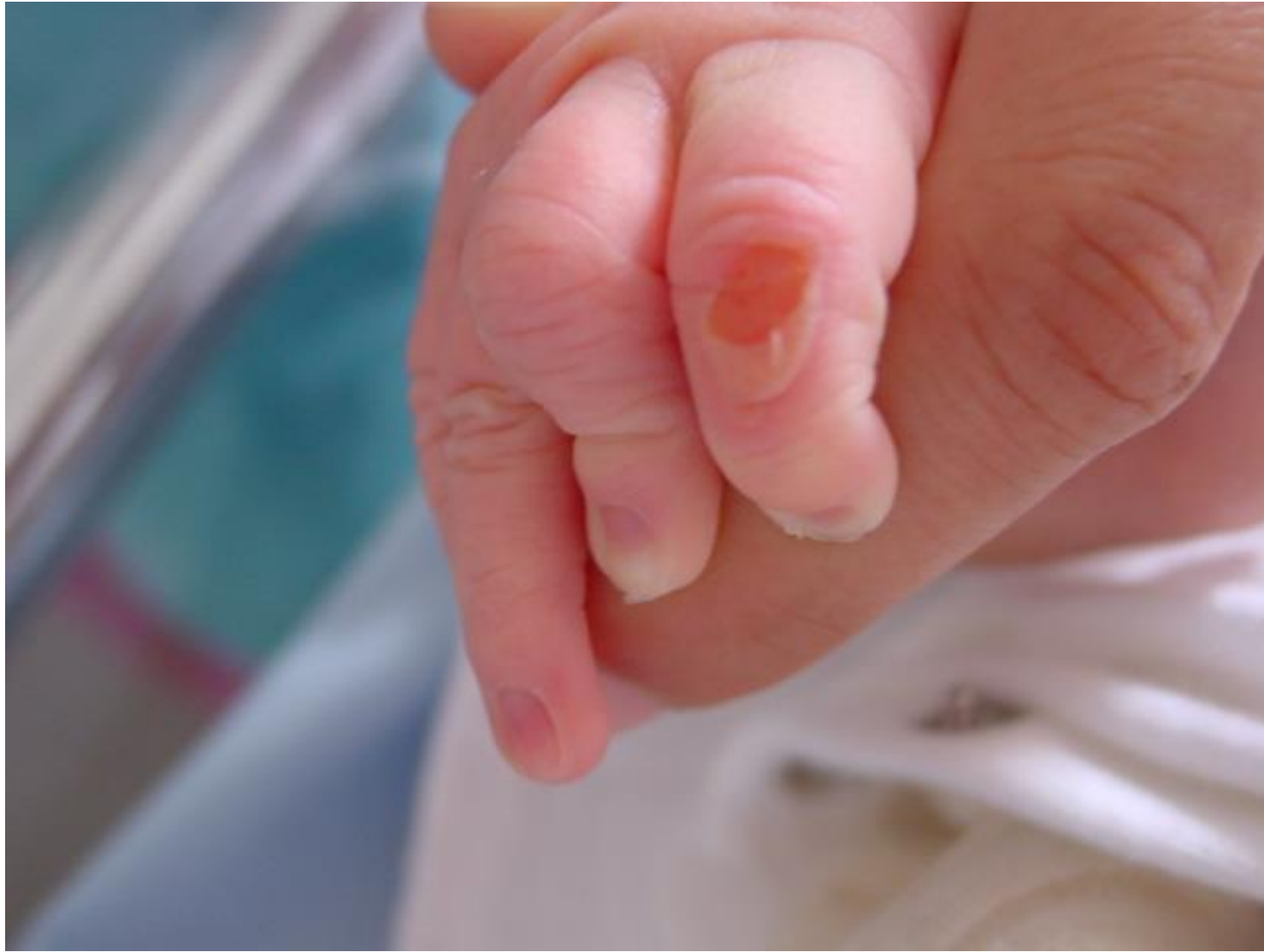

**POX SKIMUN**

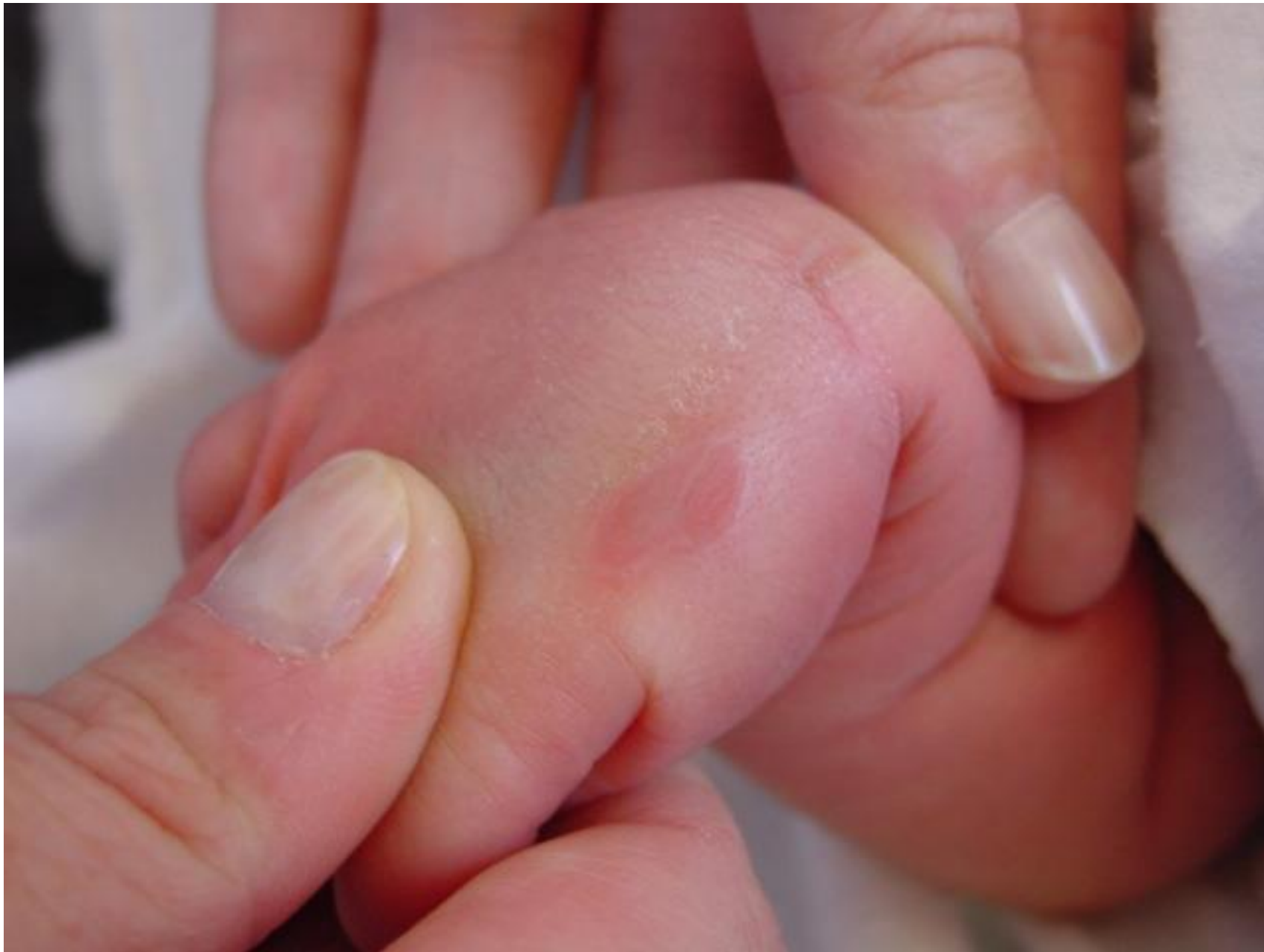



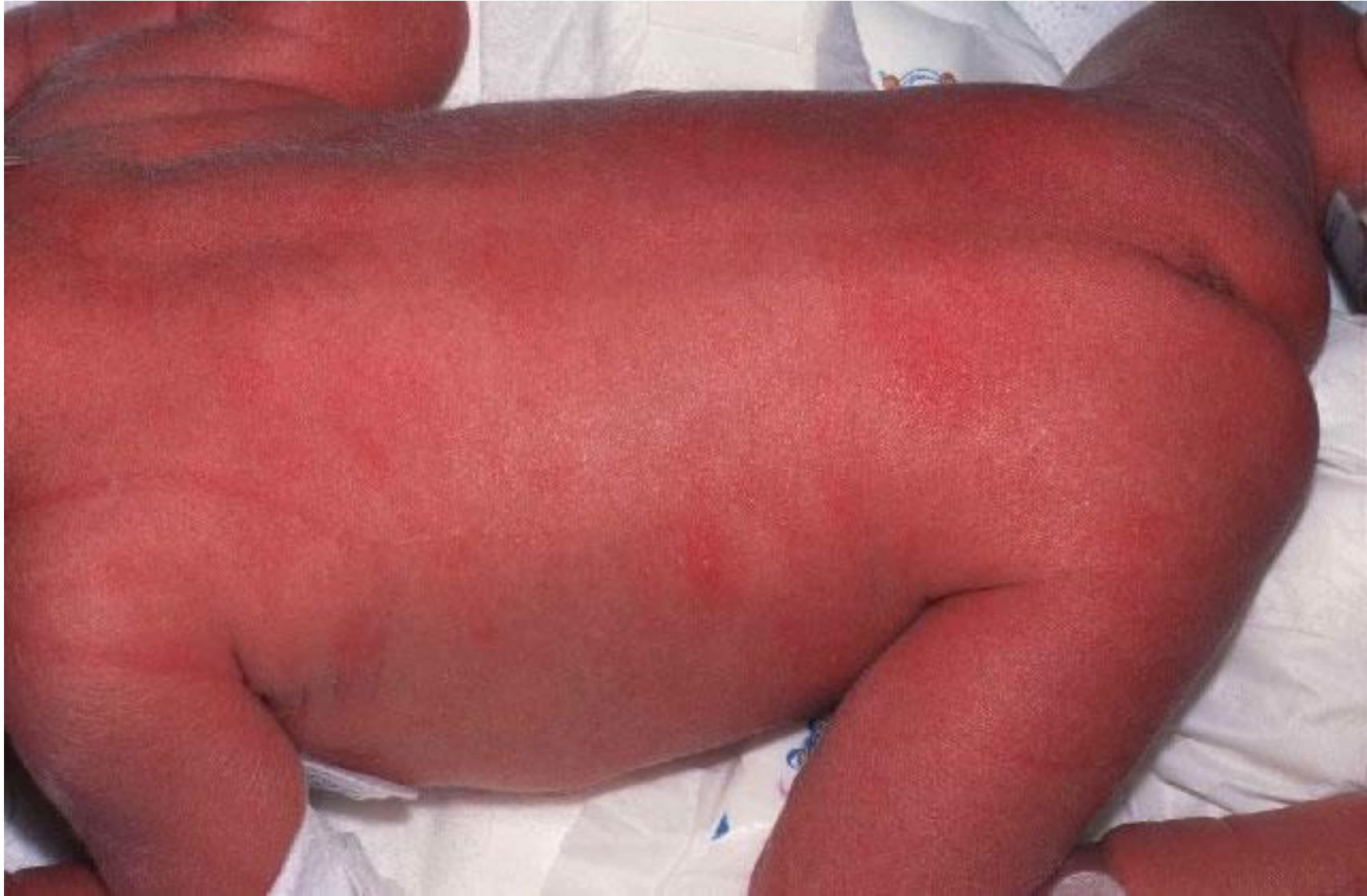**HÚĐ**

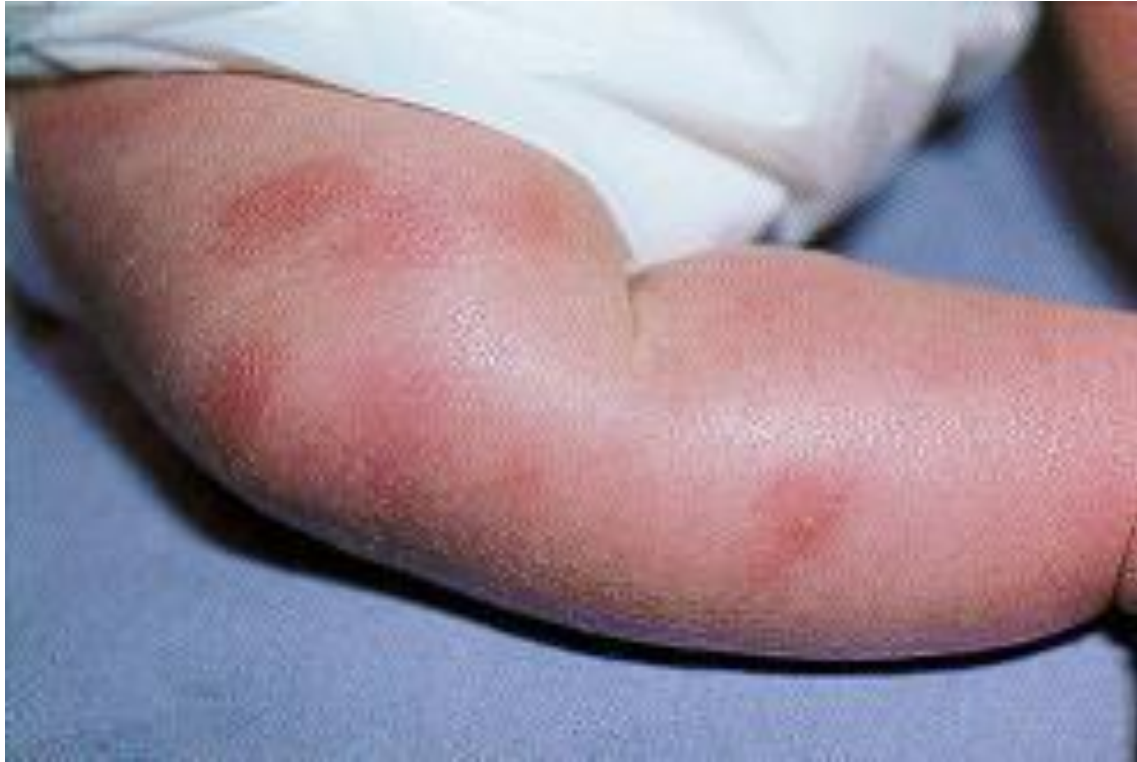

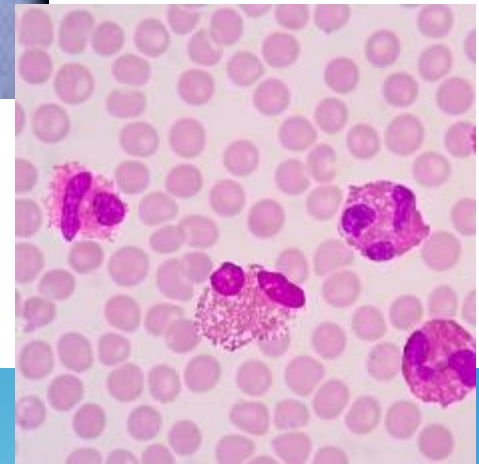

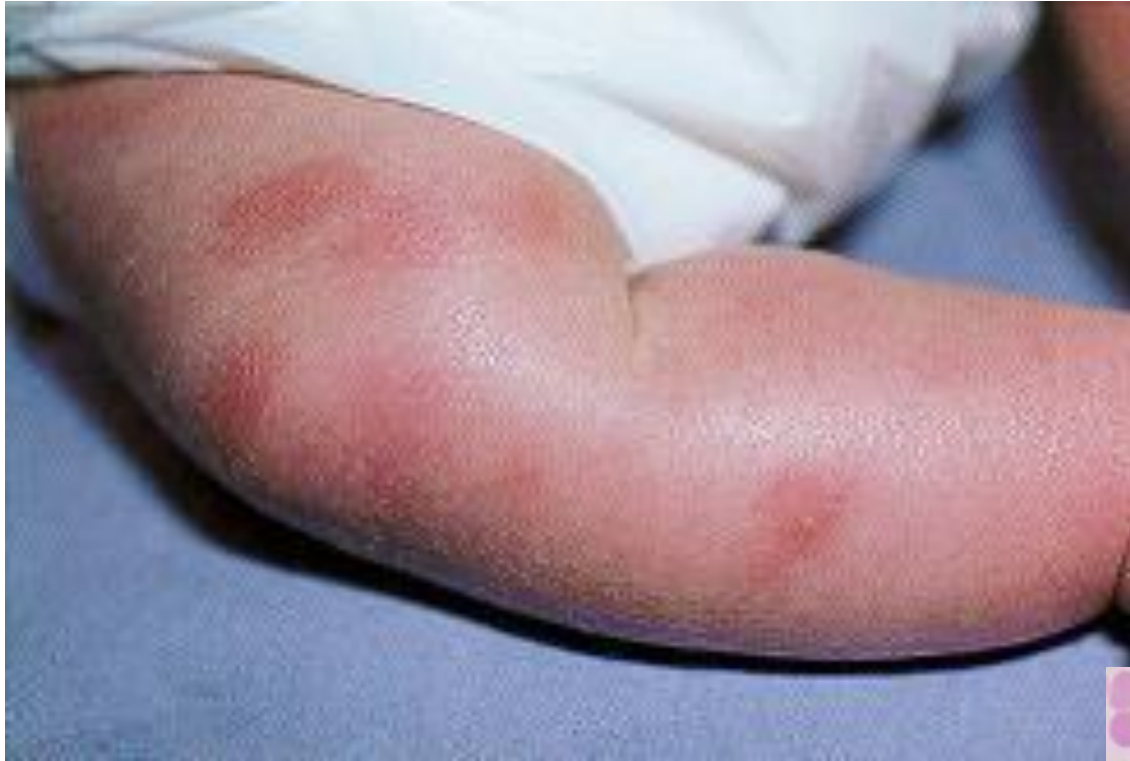




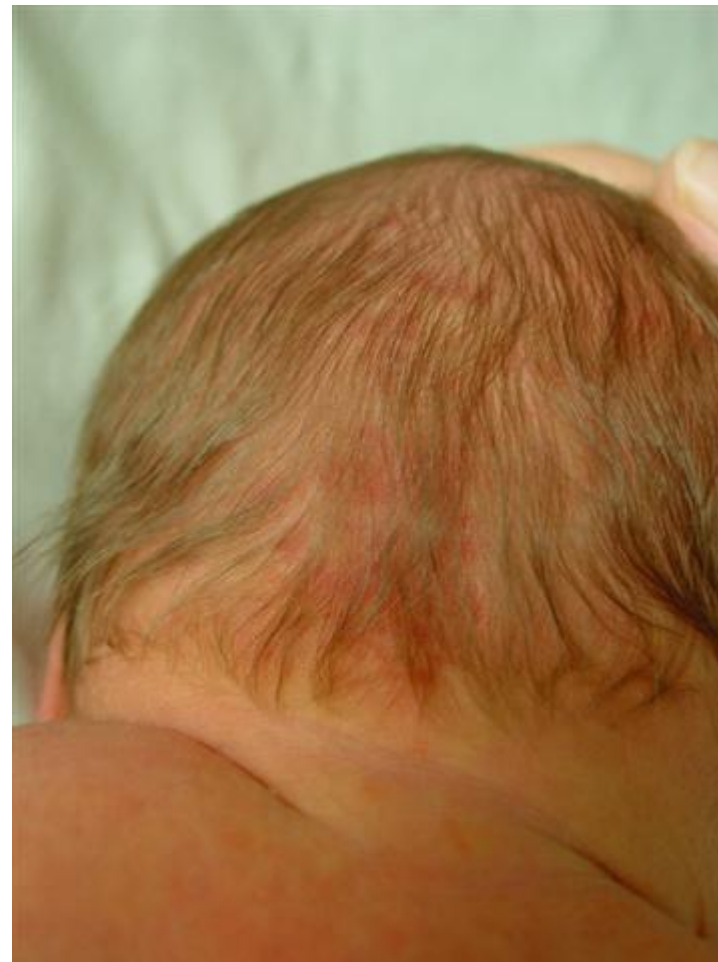
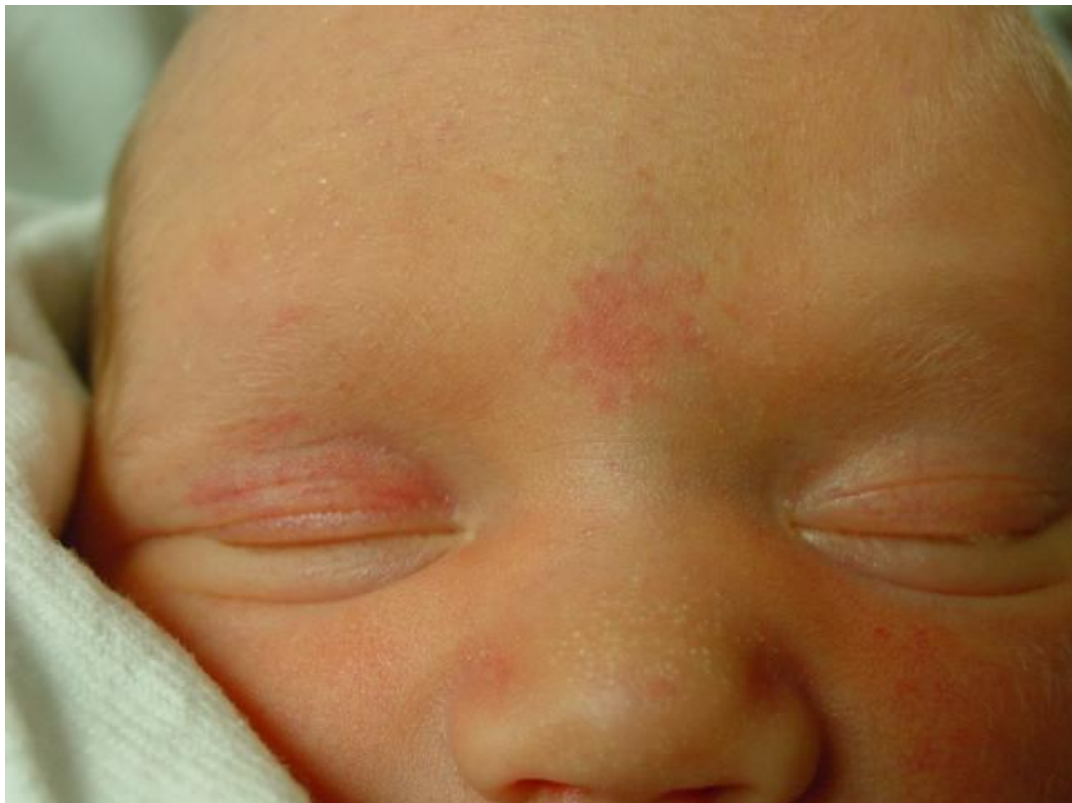




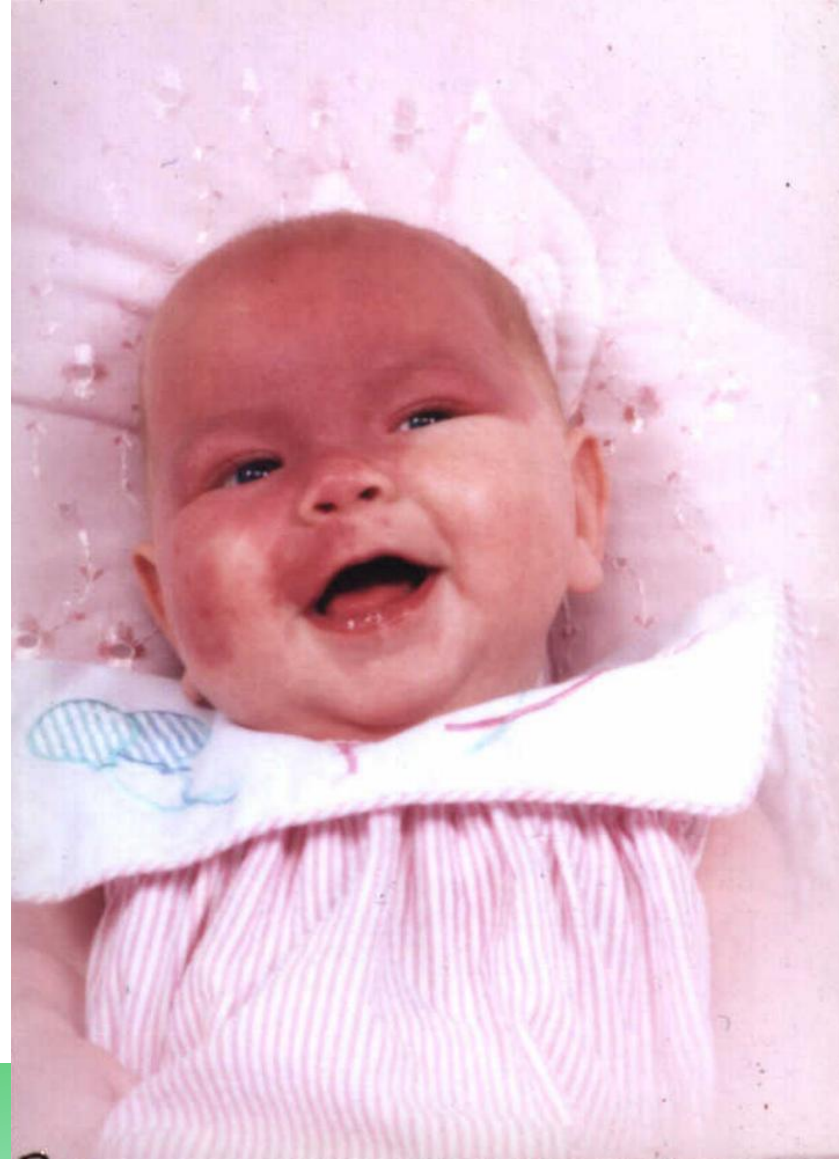# HÁRÆÐAFLÆKJA (SALMON PATCH)



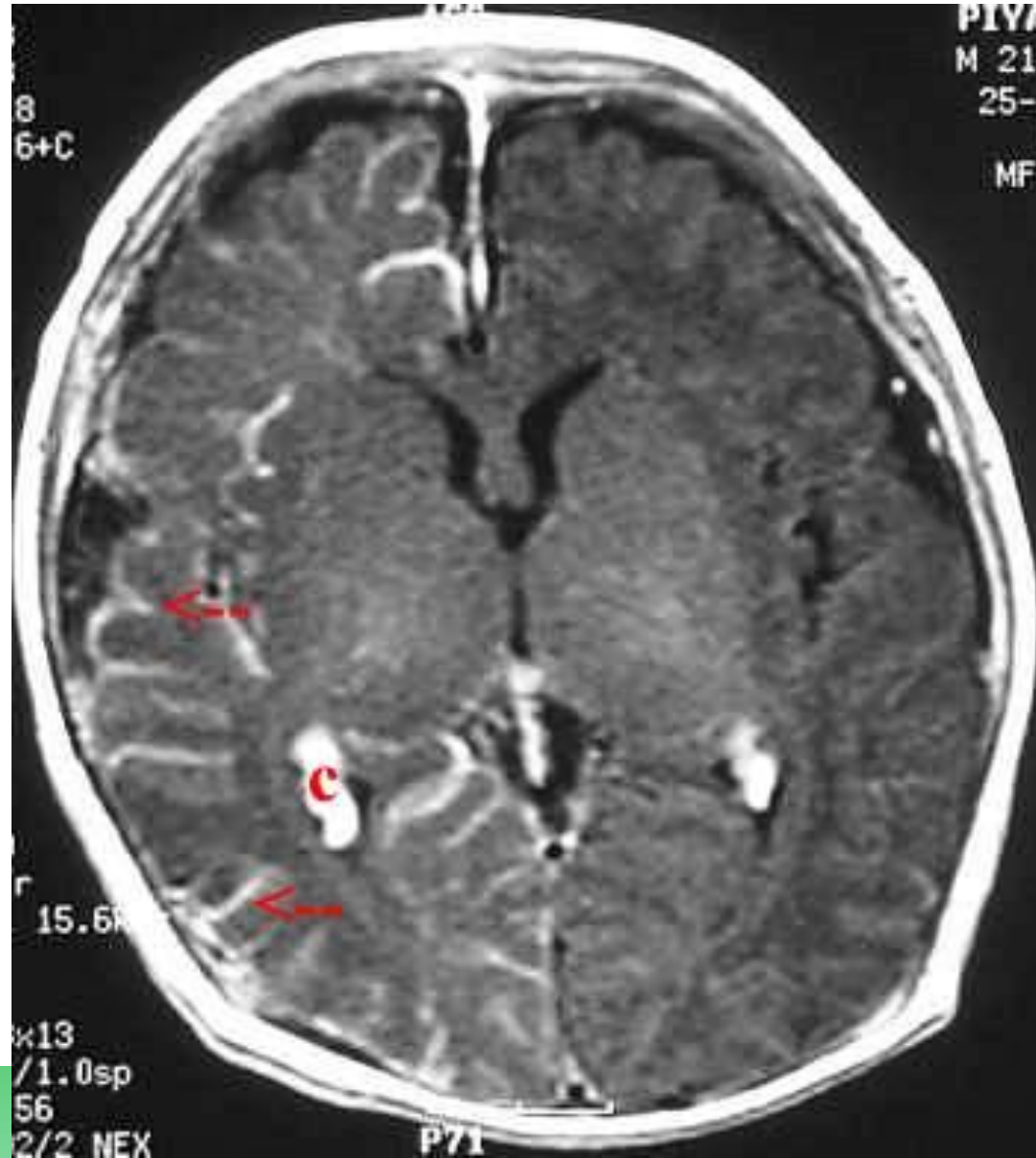


# Valbrá Sturge Weber



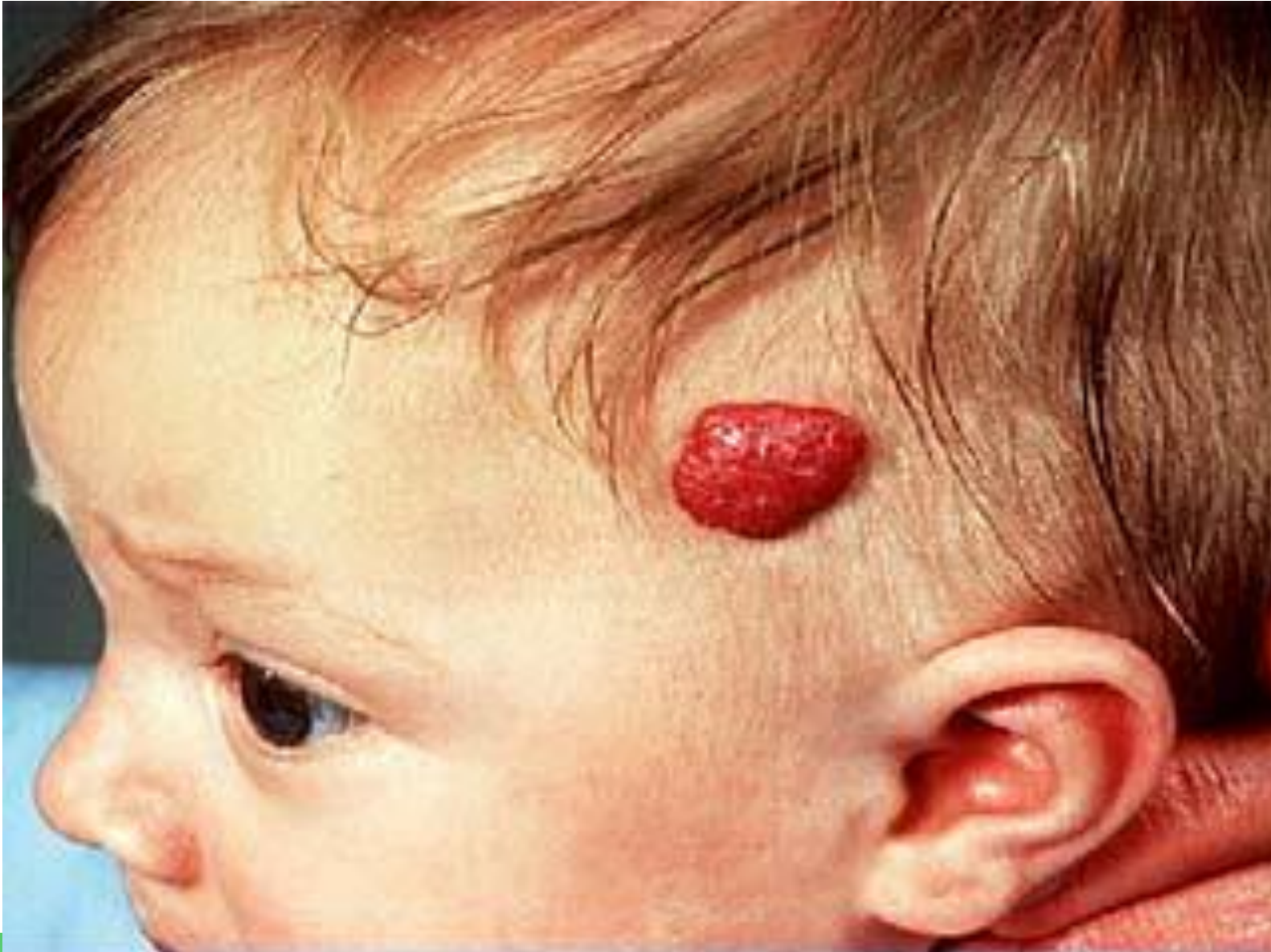# Sturge Weber

## *Kalkanir á yfirborði heila*

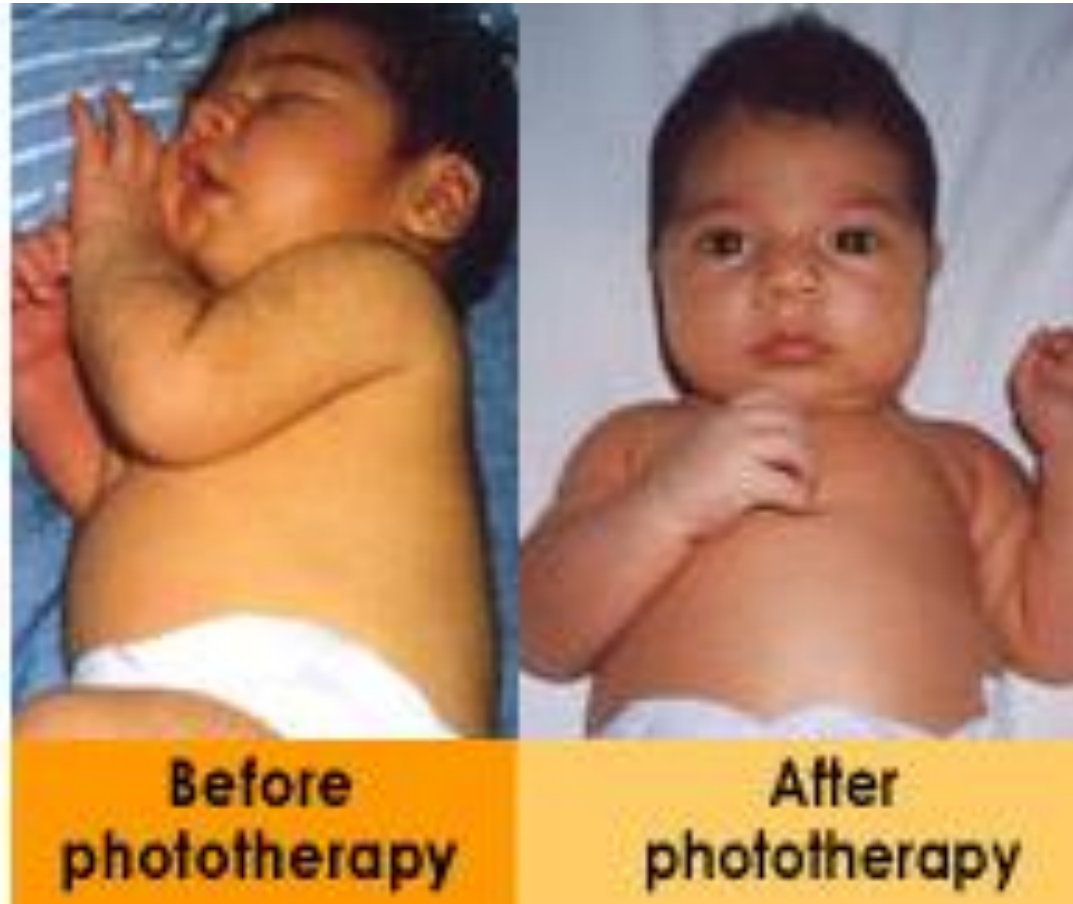


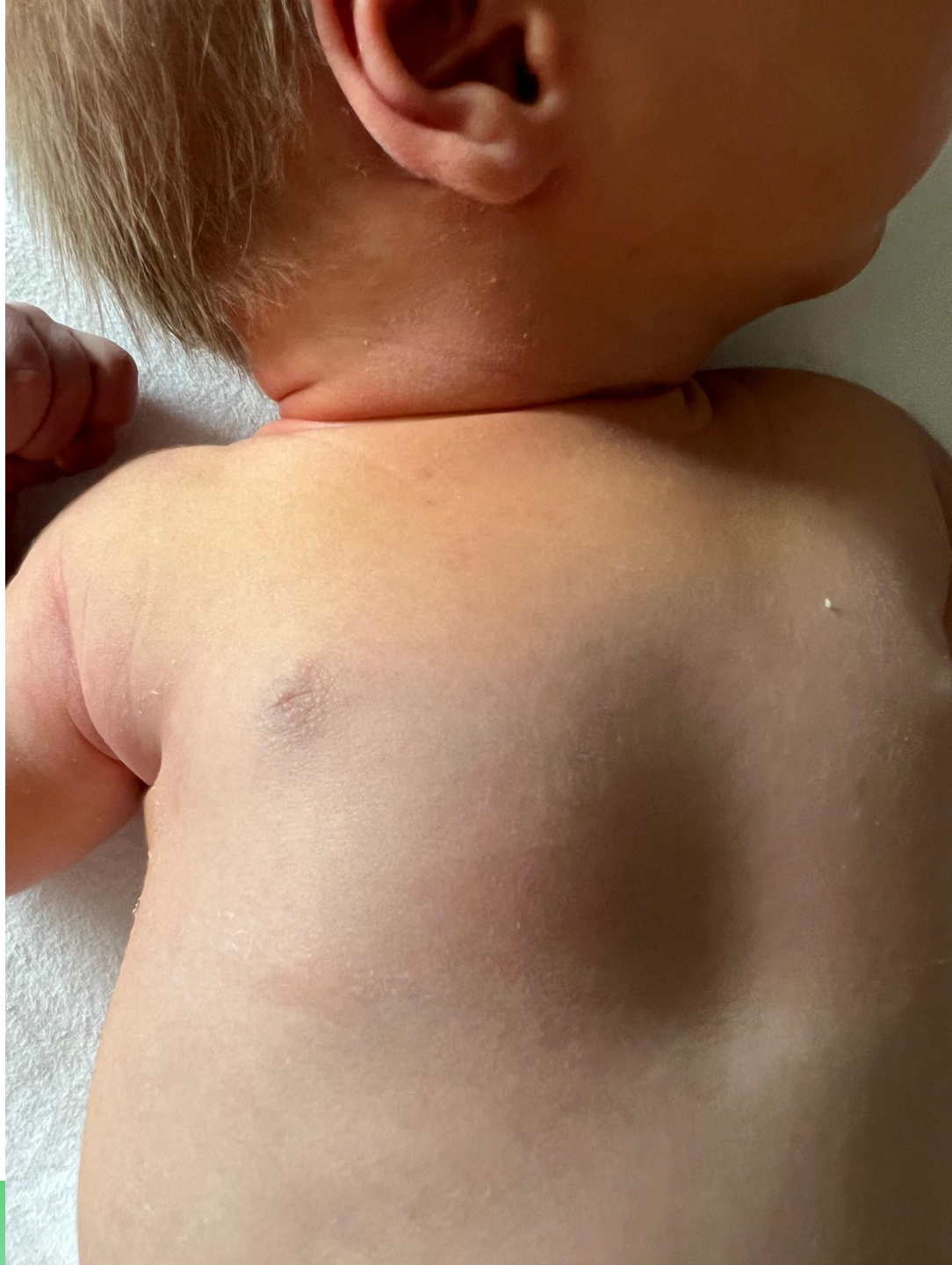
# Strawberry hemangioma

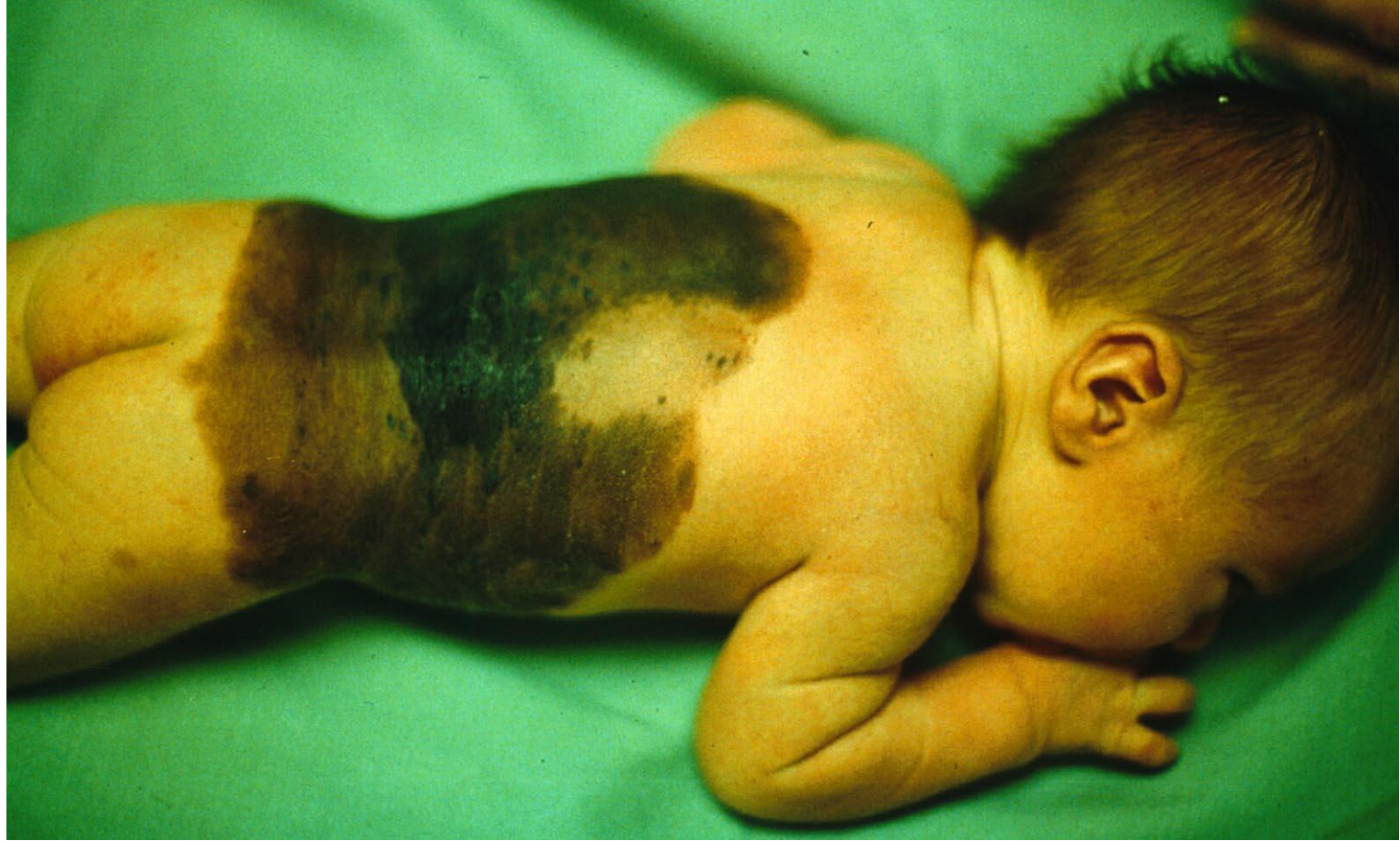

# Nýburagula









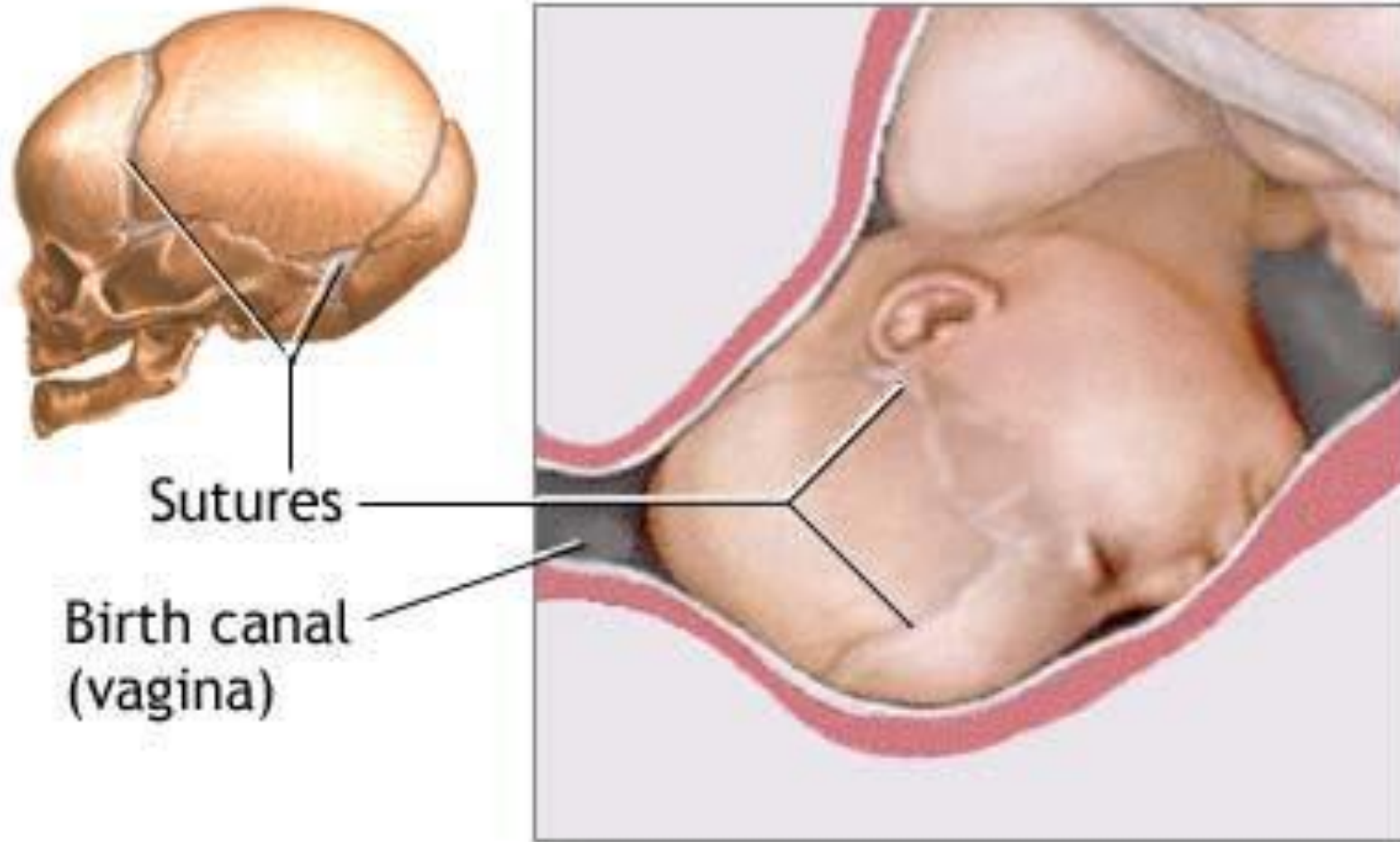
# SKOÐUN NÝBURA

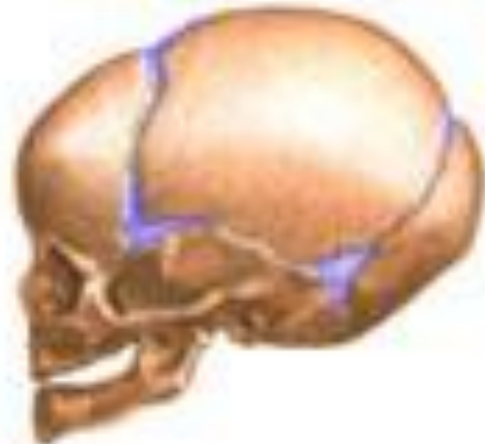- Höfuð
  - Stærð, lögun
  - „Molding“
  - Merki um fæðingaáverka
- Augu
- Munnur og kok
  - Gómur
  - Epstein's perlur

HÖFUÐ

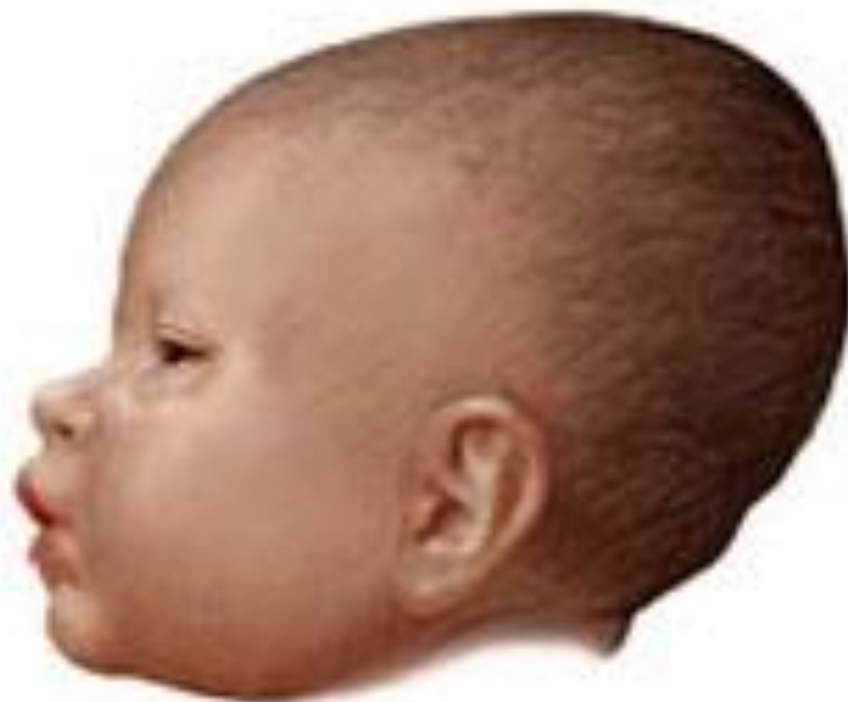

# Fetal head molding

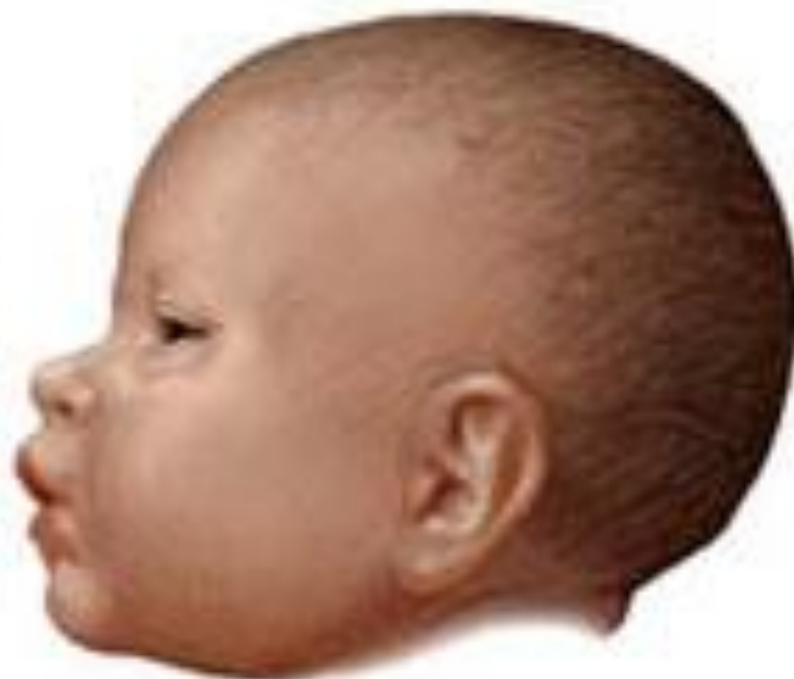



Fontanelles  
in blue

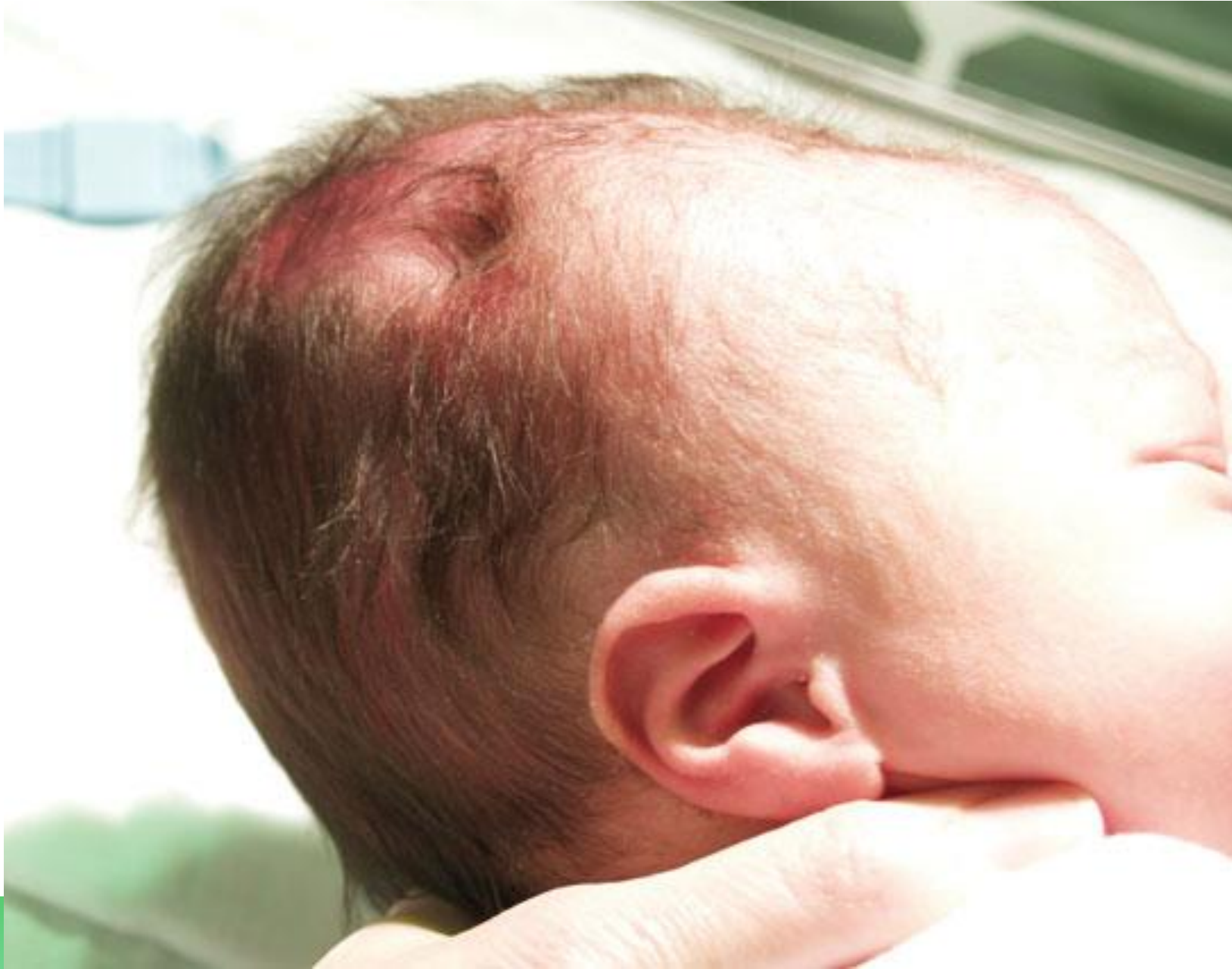

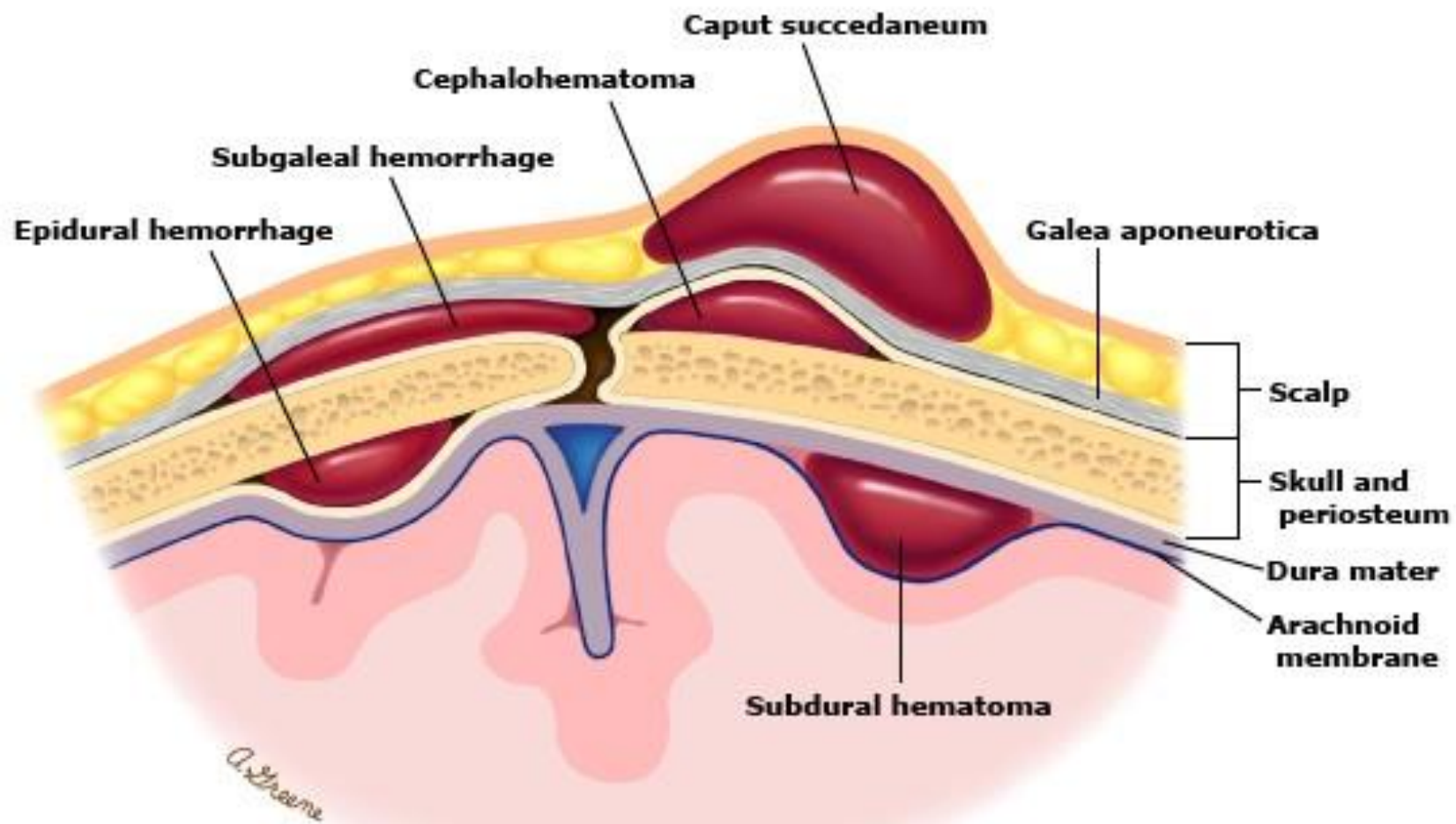
Minutes after birth



After 24 hours

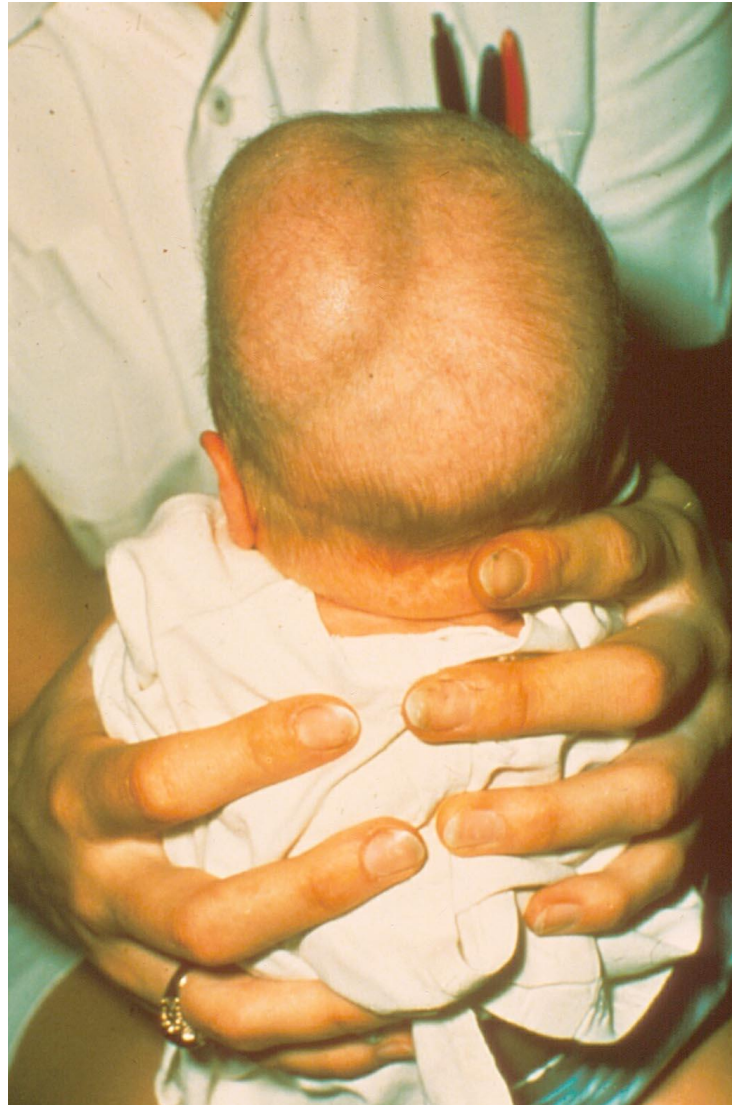# Caput succedaneum



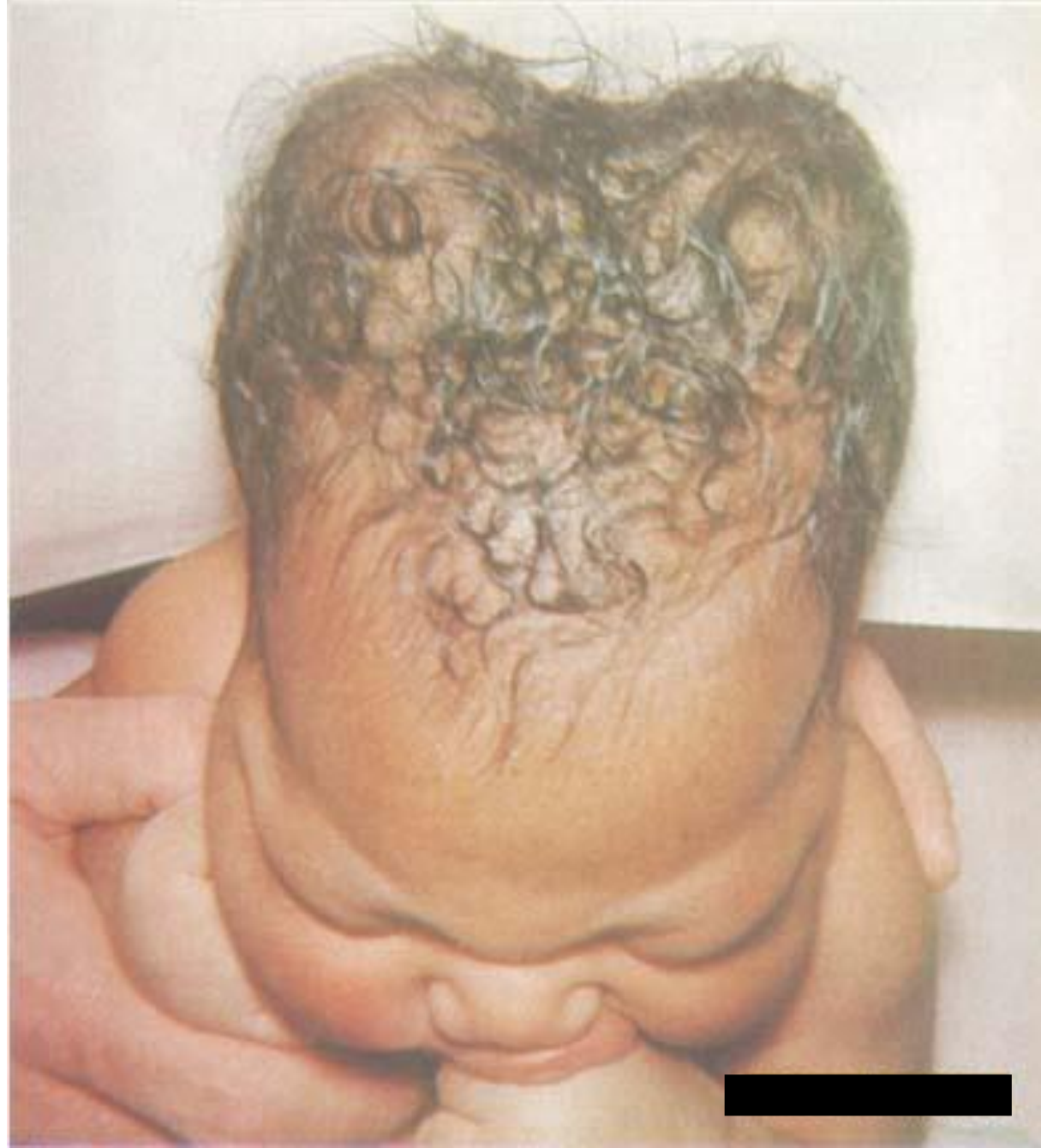



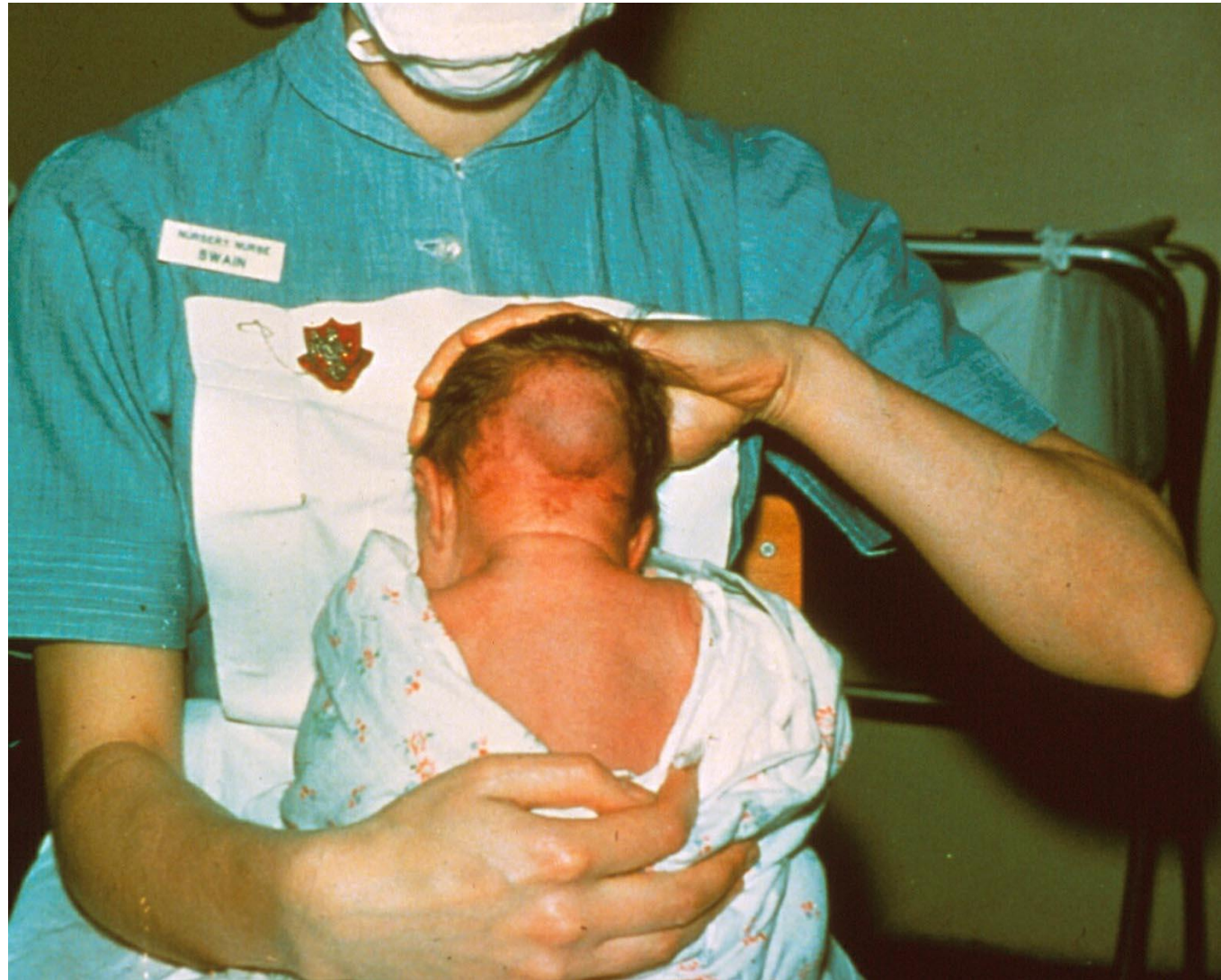# Cephalhematoma

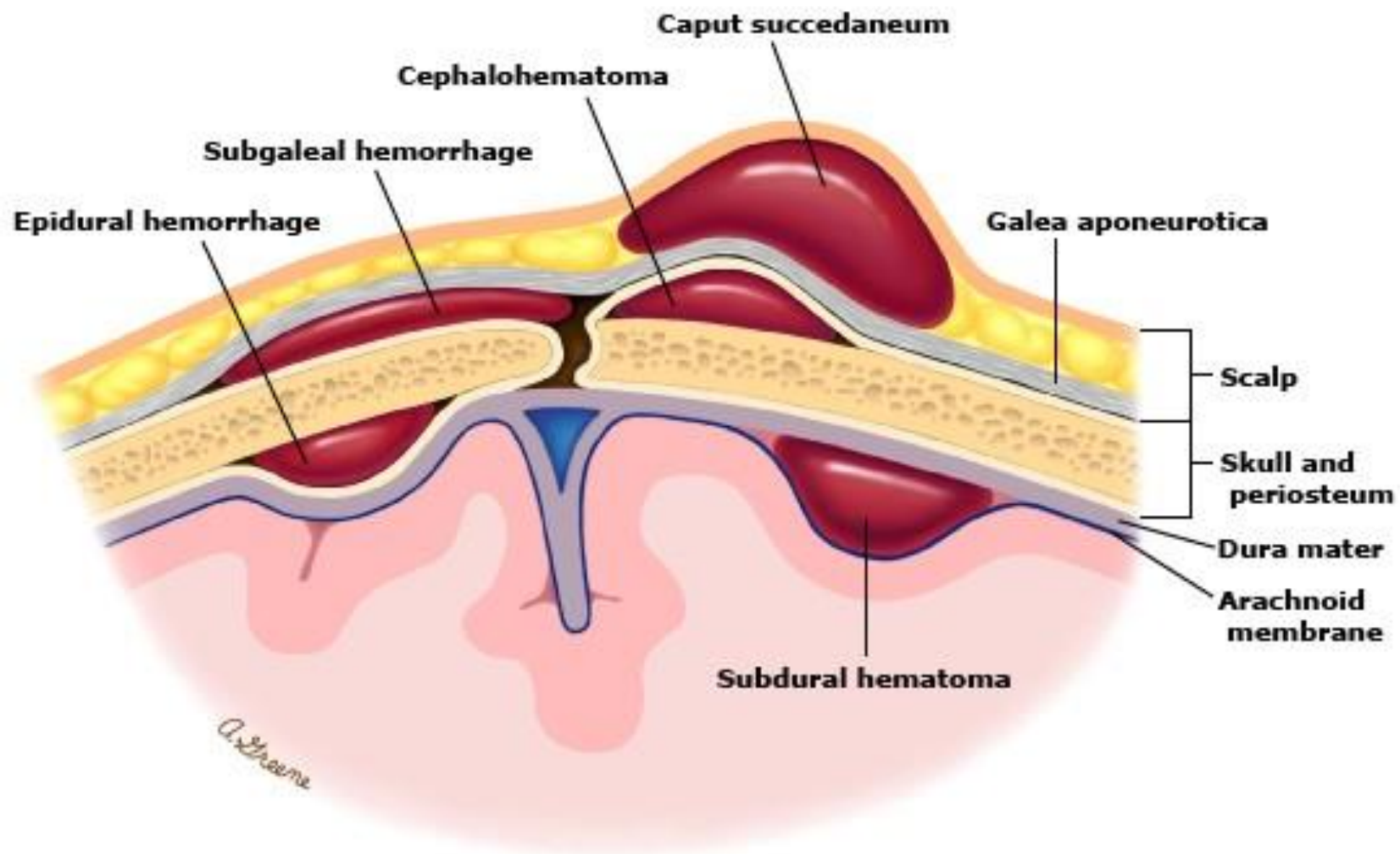






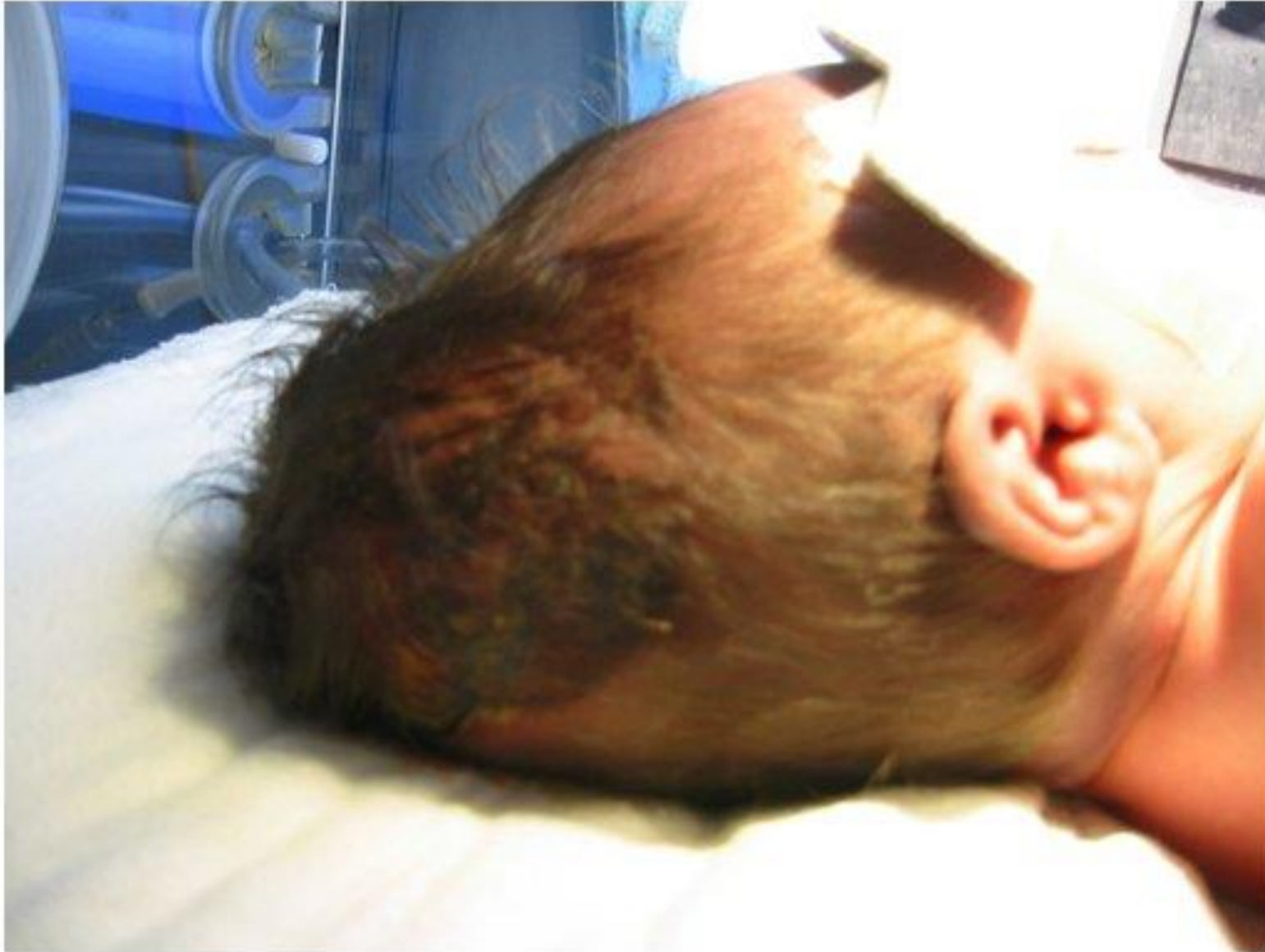# Cephalhematoma



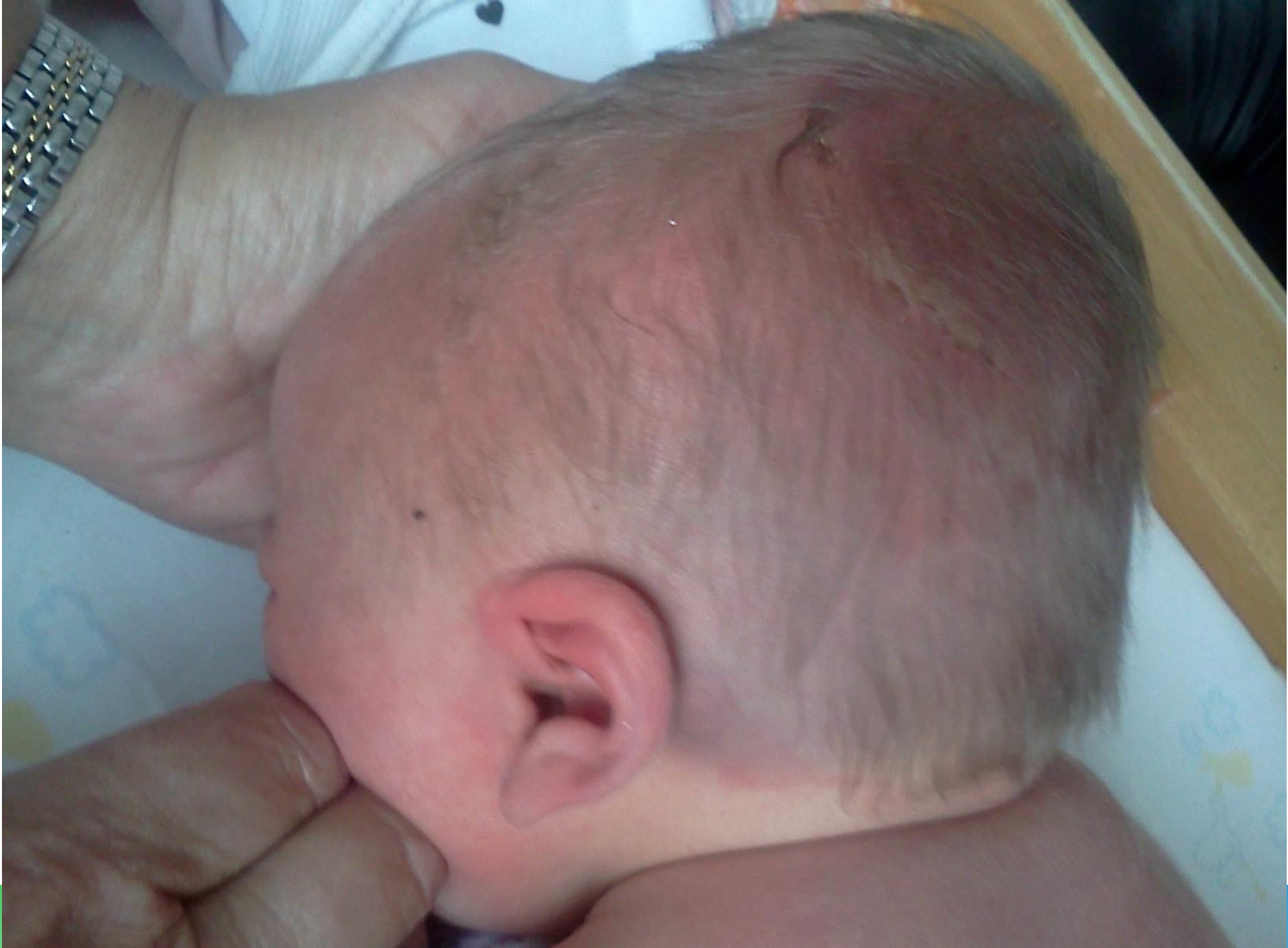



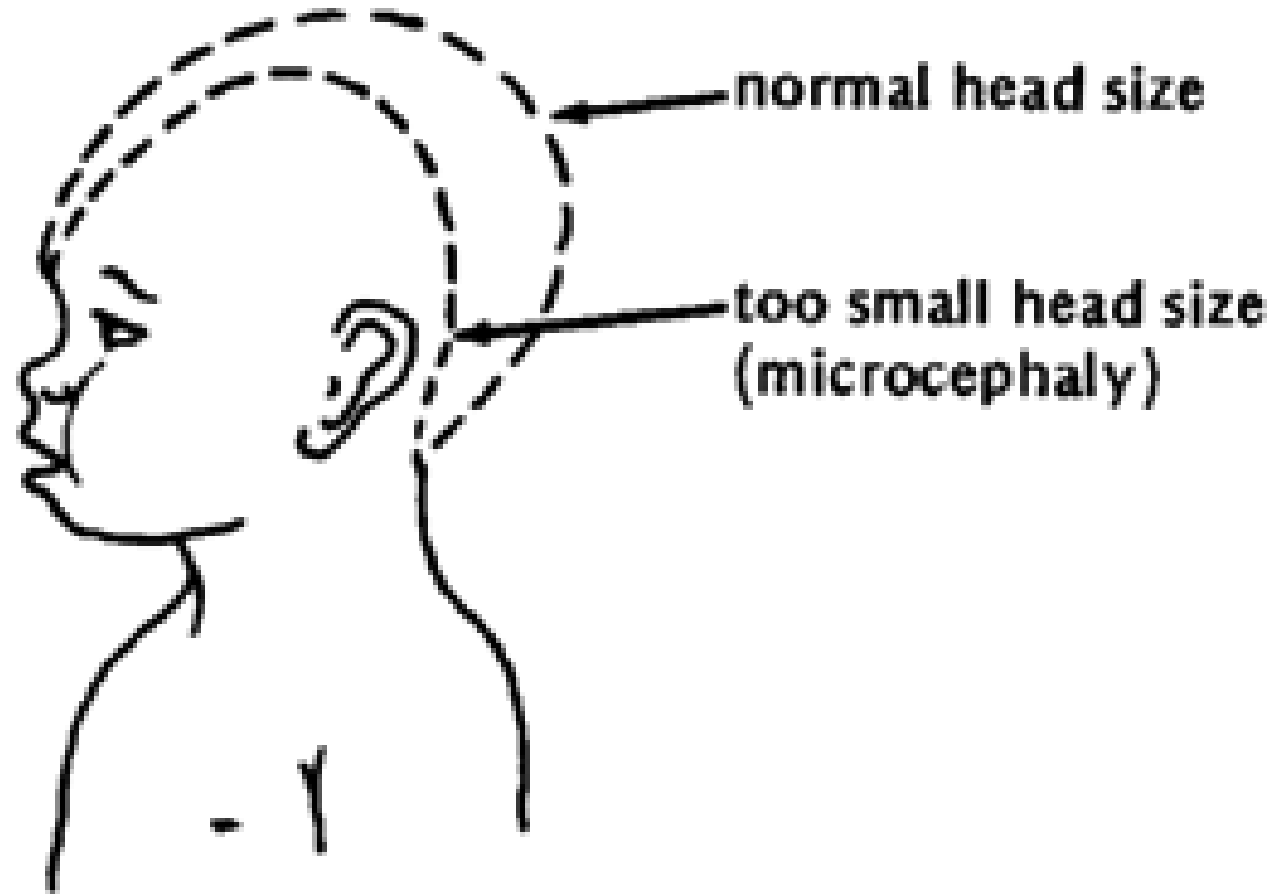
# Subgaleal blæðing



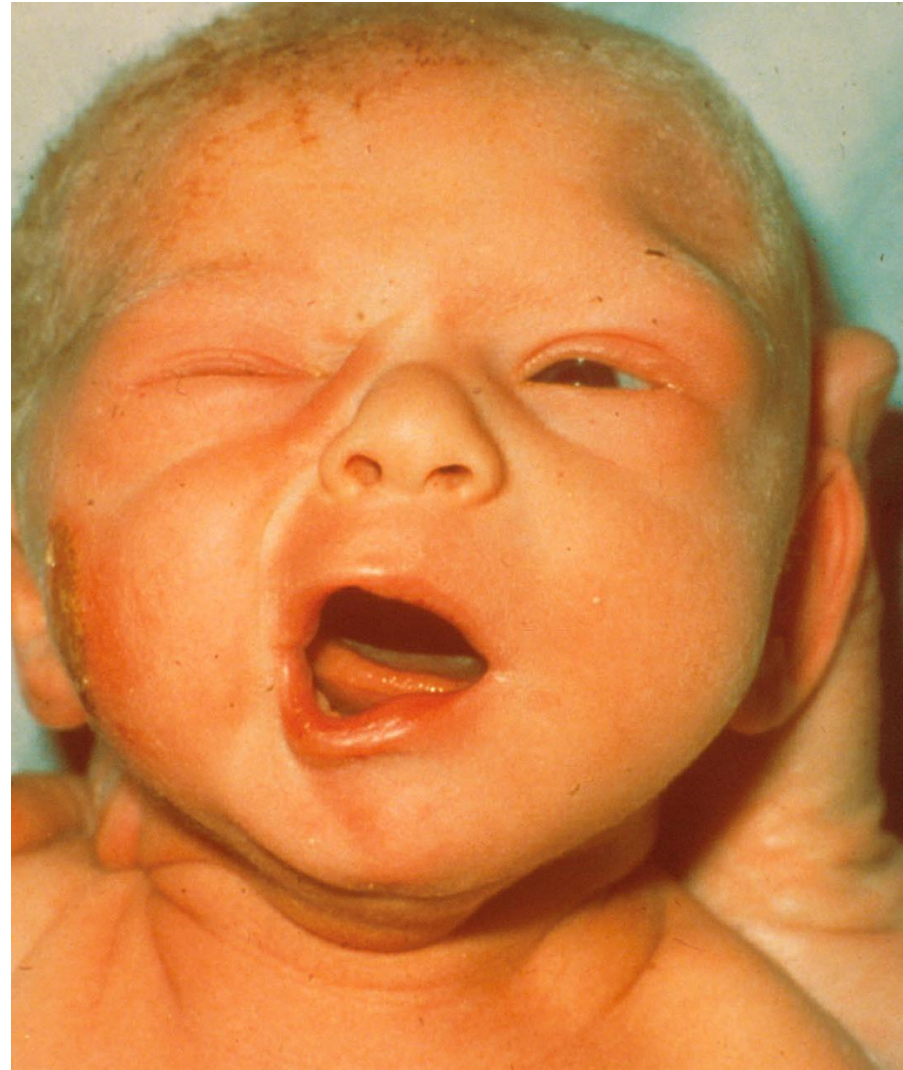



# Smáhöfði Microcephaly

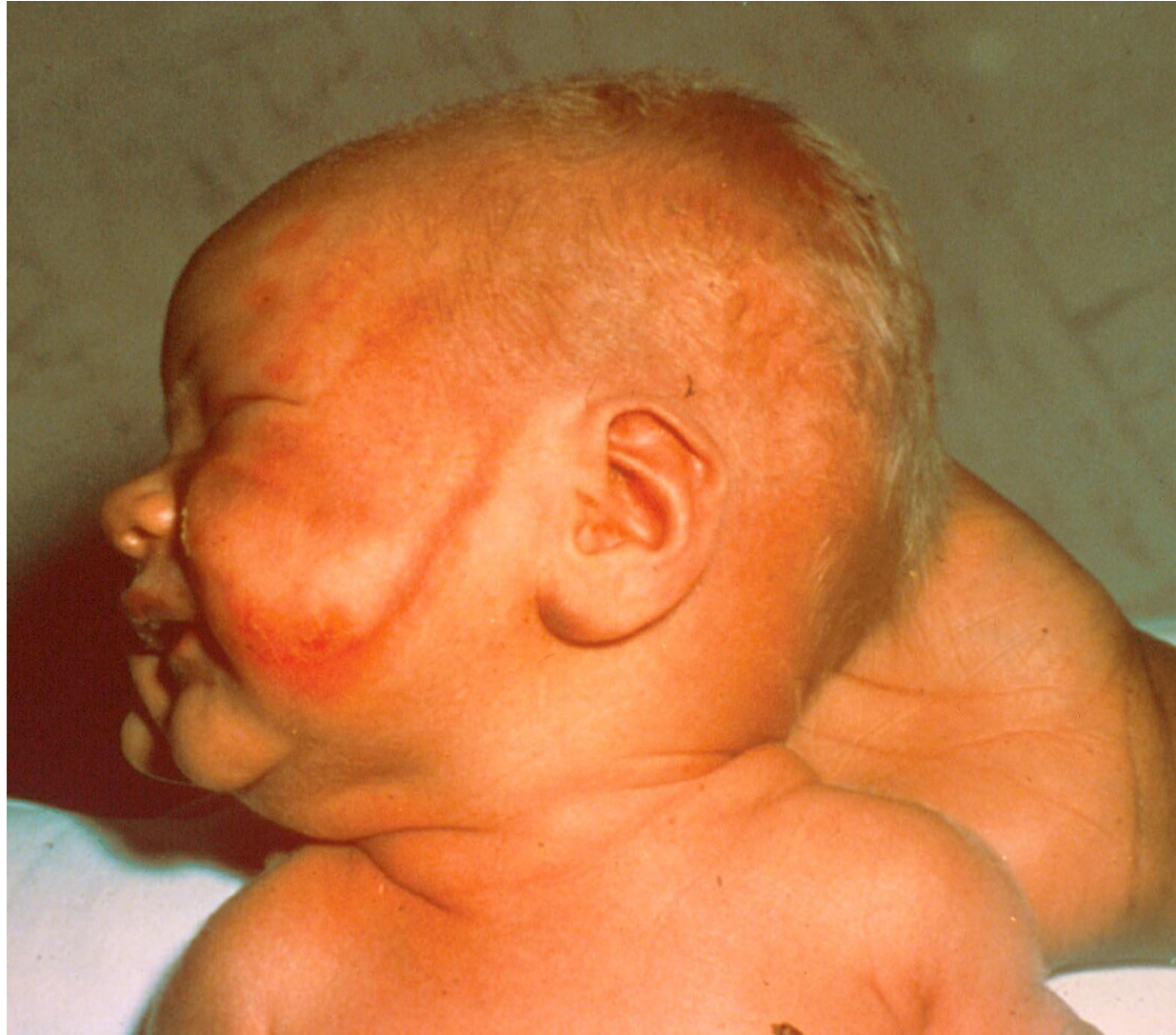

## Lömun við andlitstaugar



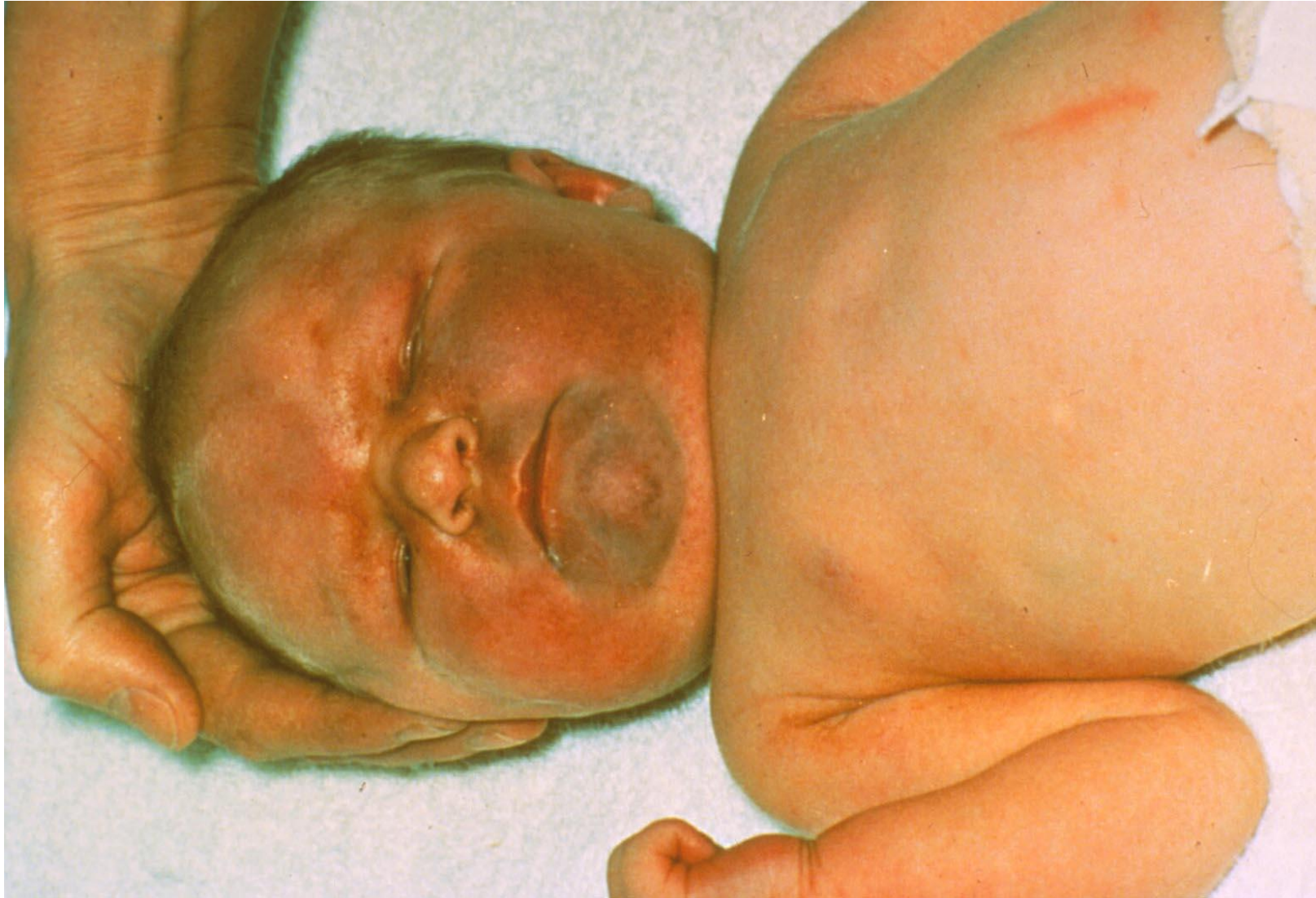

# Far eftir töng

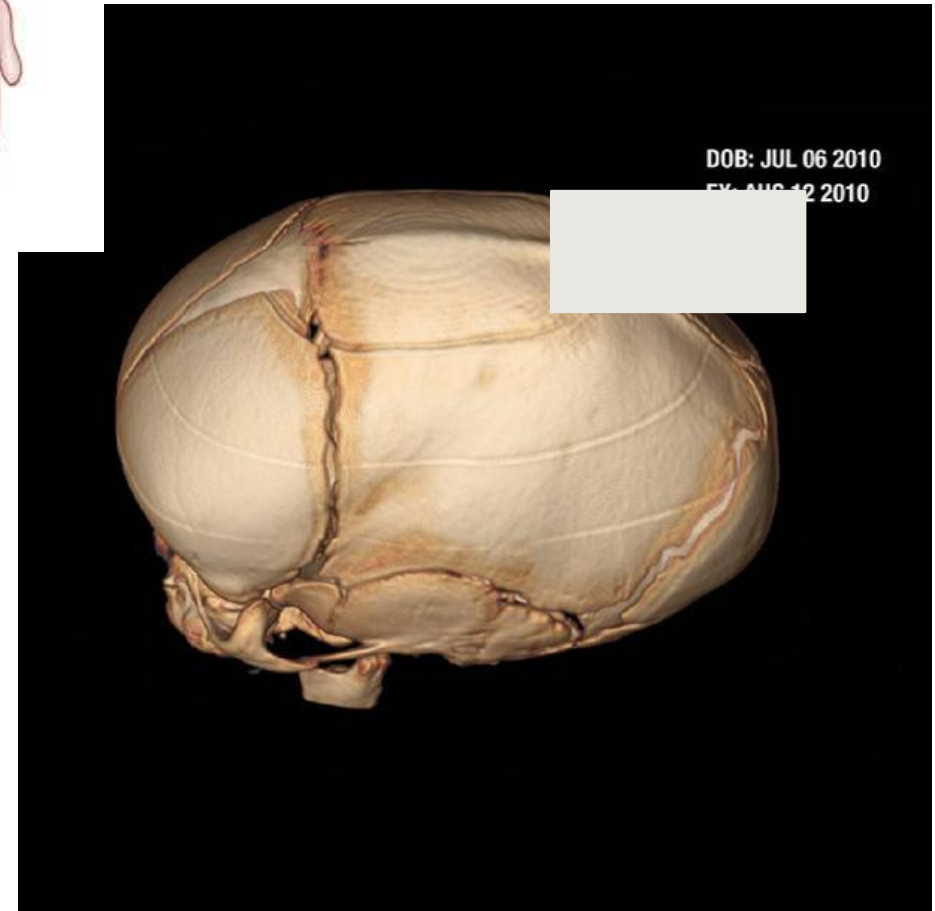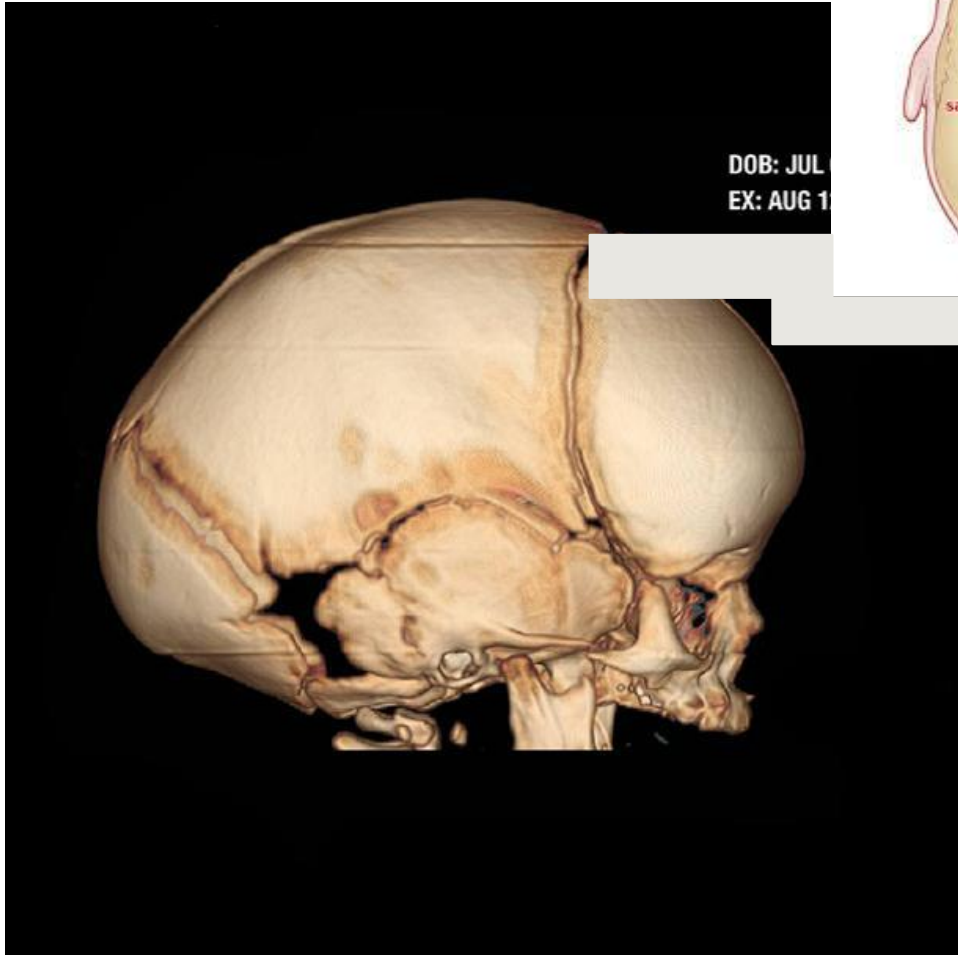
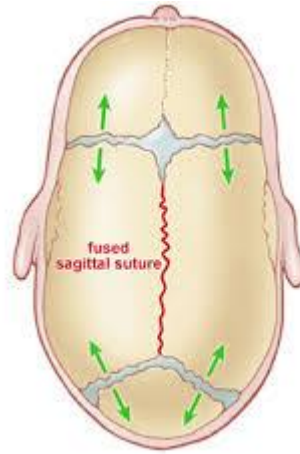




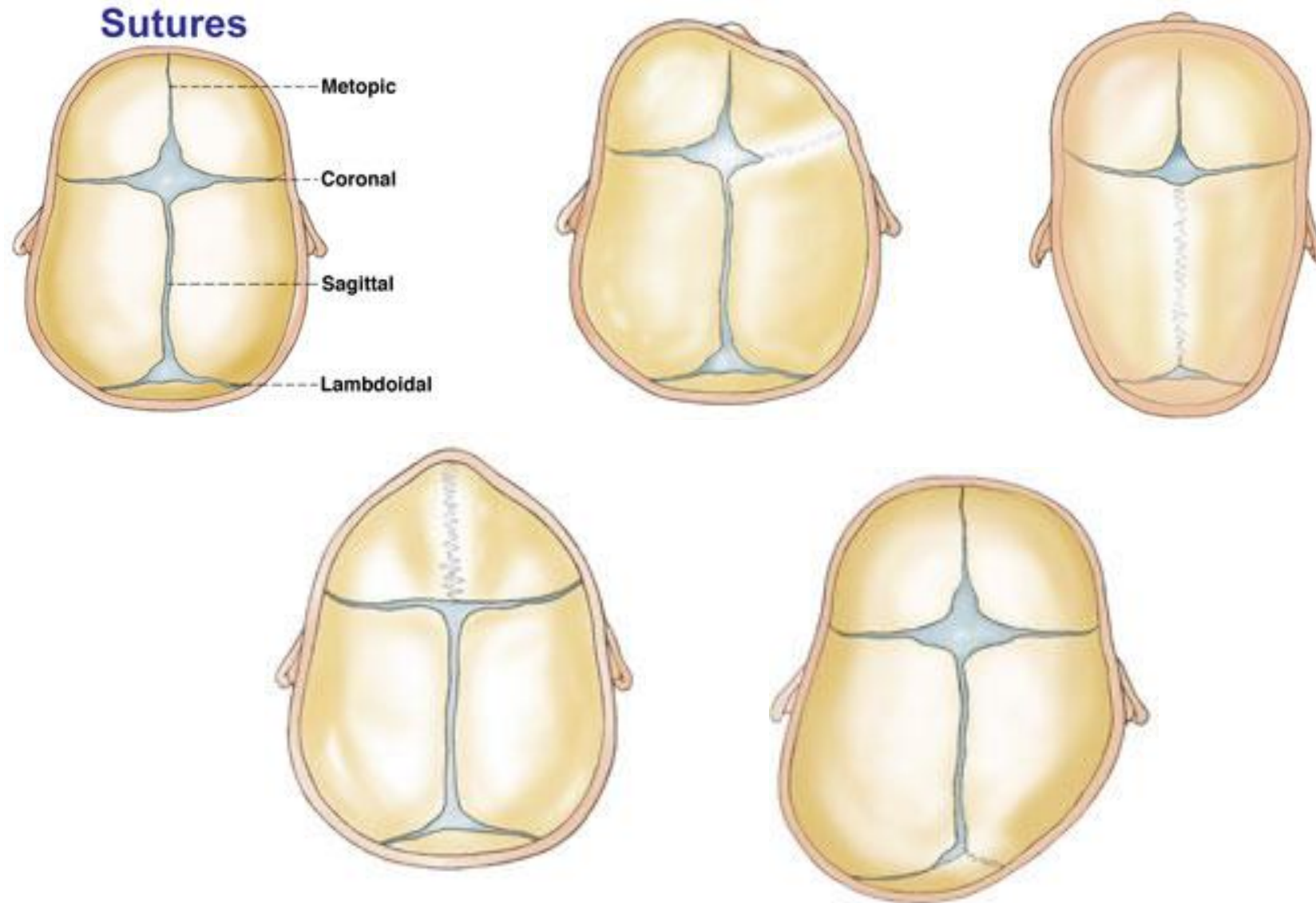
# Mar á andliti eftir andlitsfæðingu



# Sagittal craniosynostosis

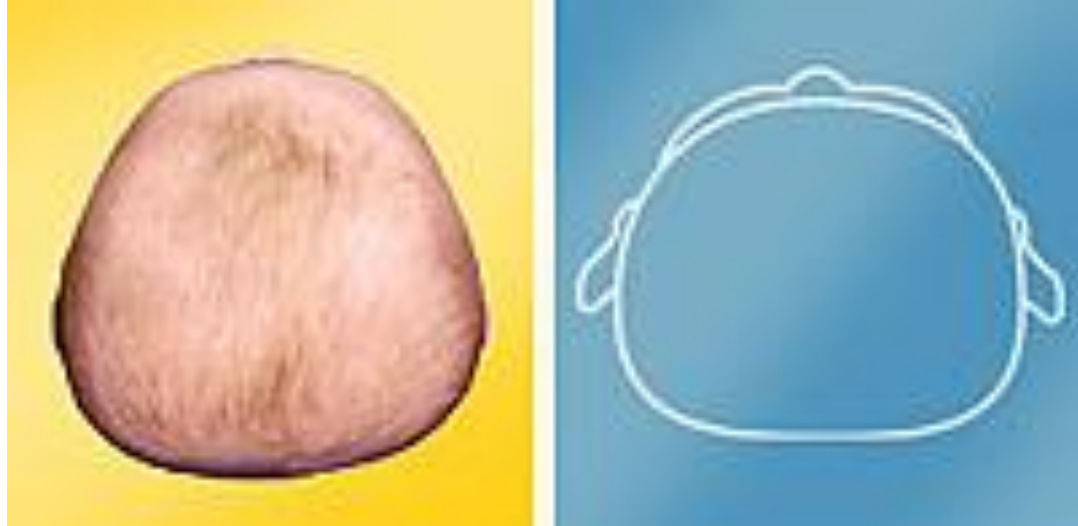
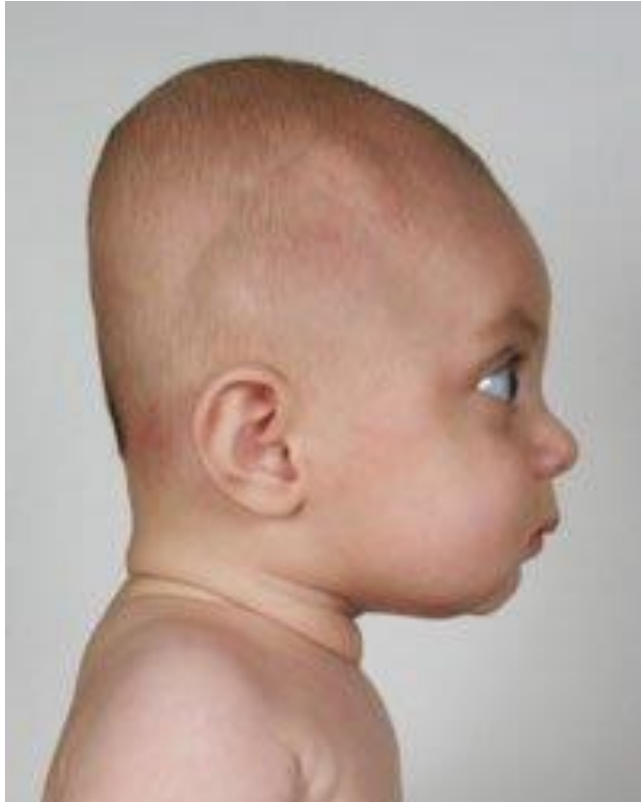
# Craniosynostosis



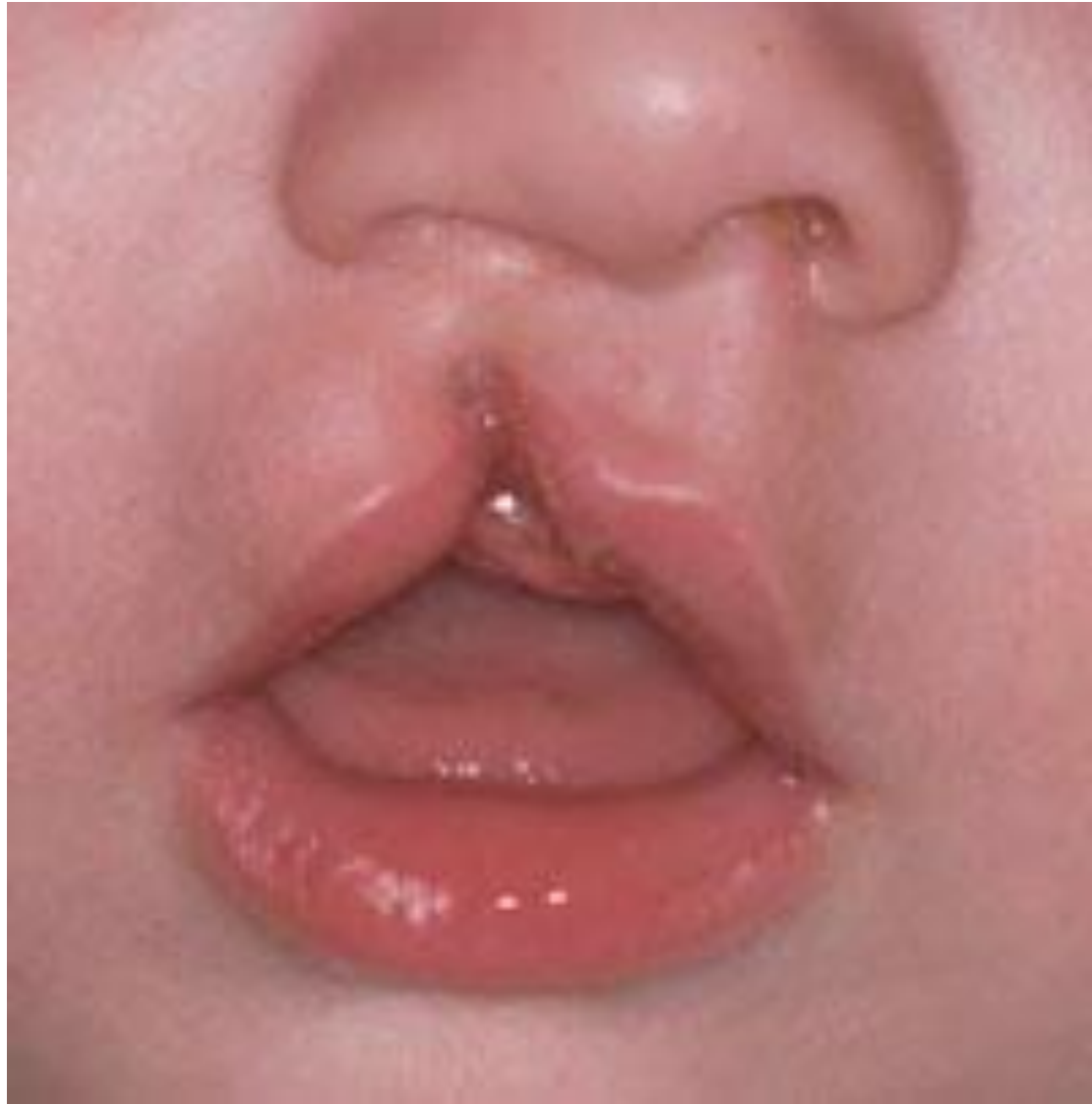

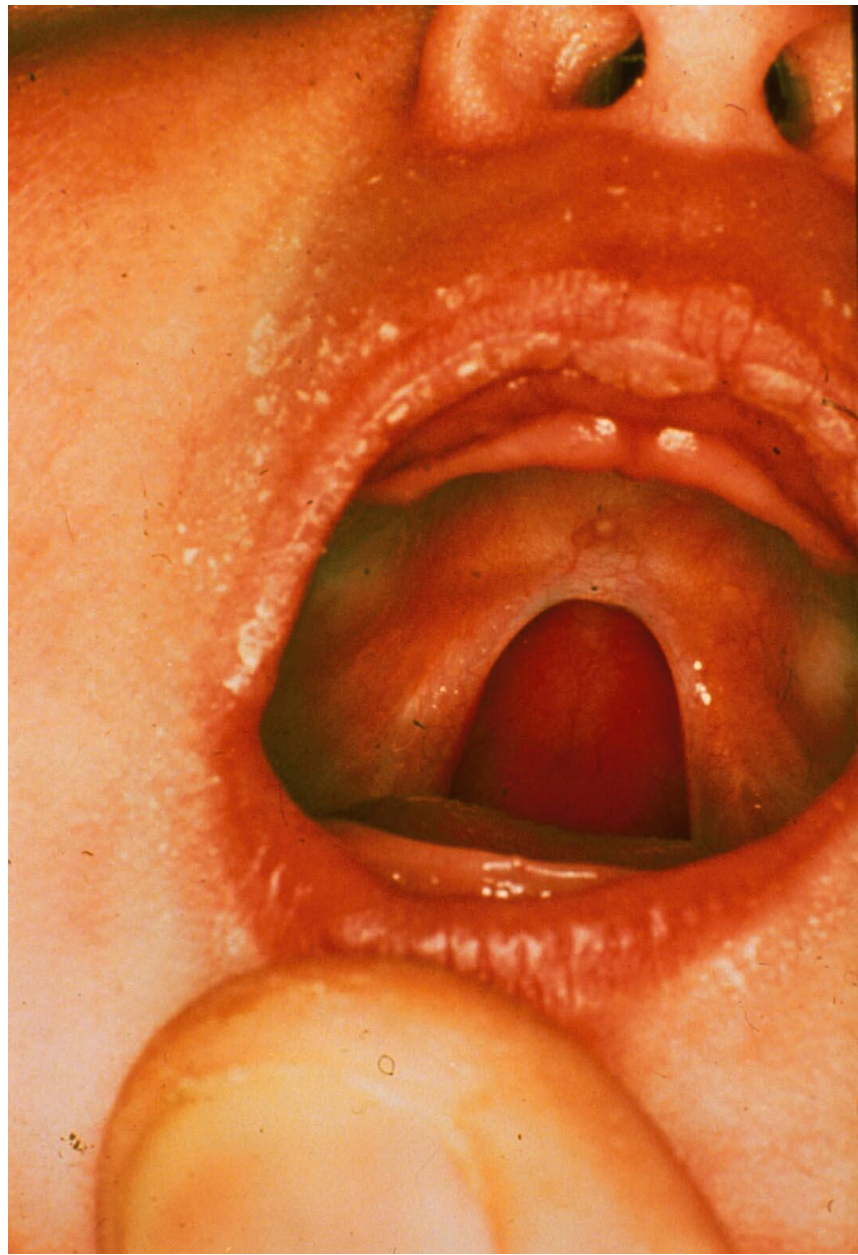# Bilateral coronal craniosynostosis Brachicephalia



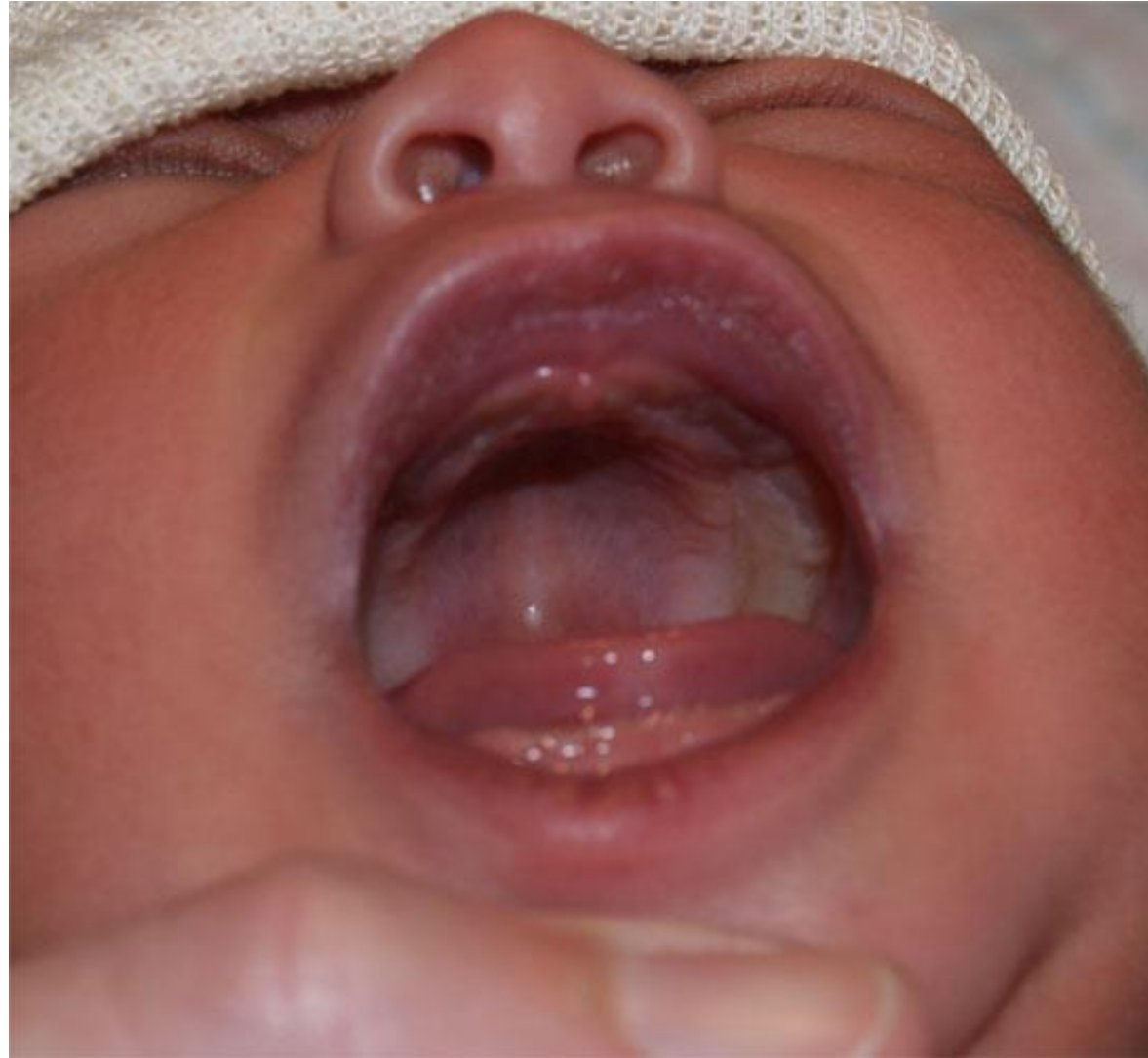

**ANDLIT**



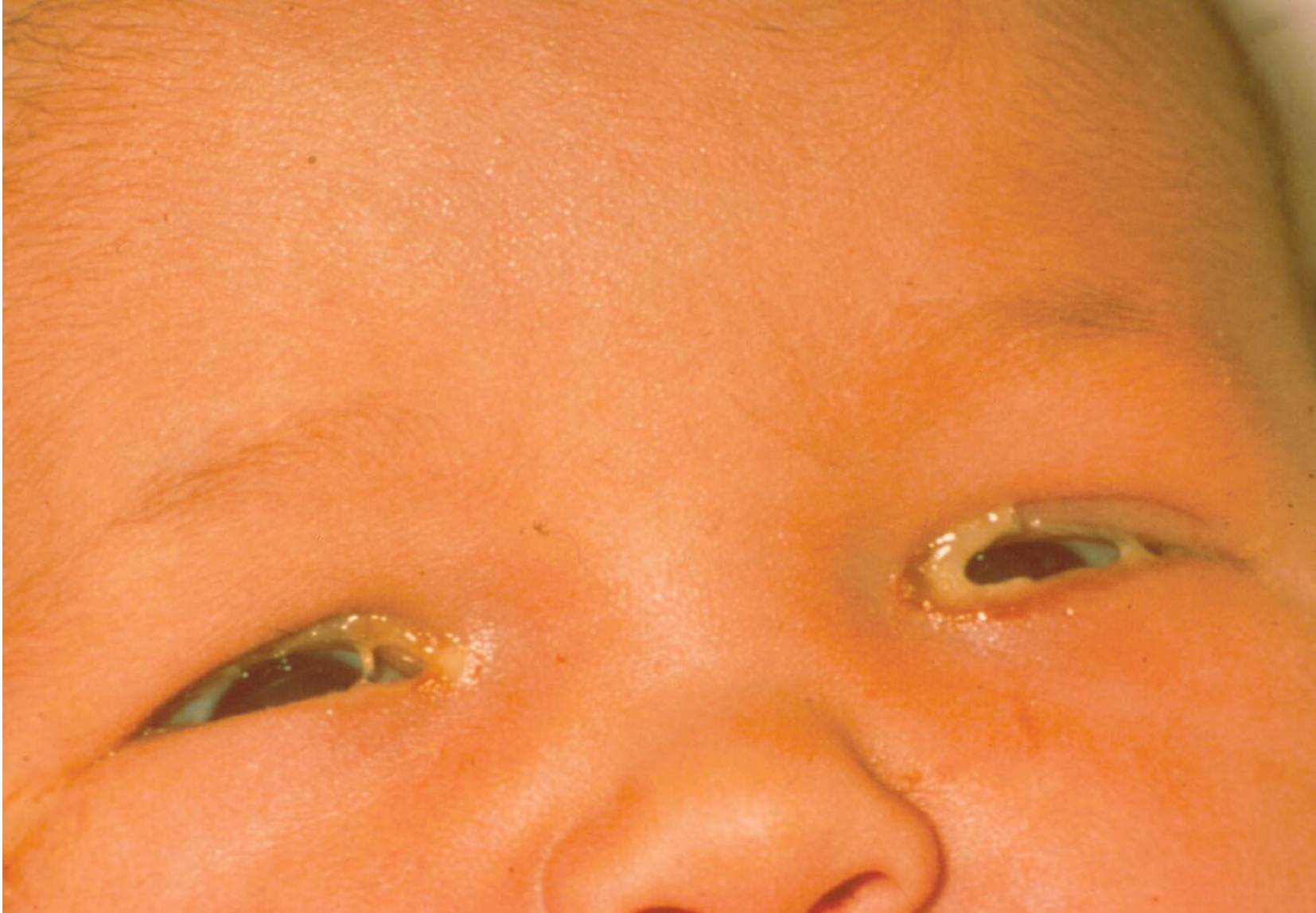

## Ebstein's pearl

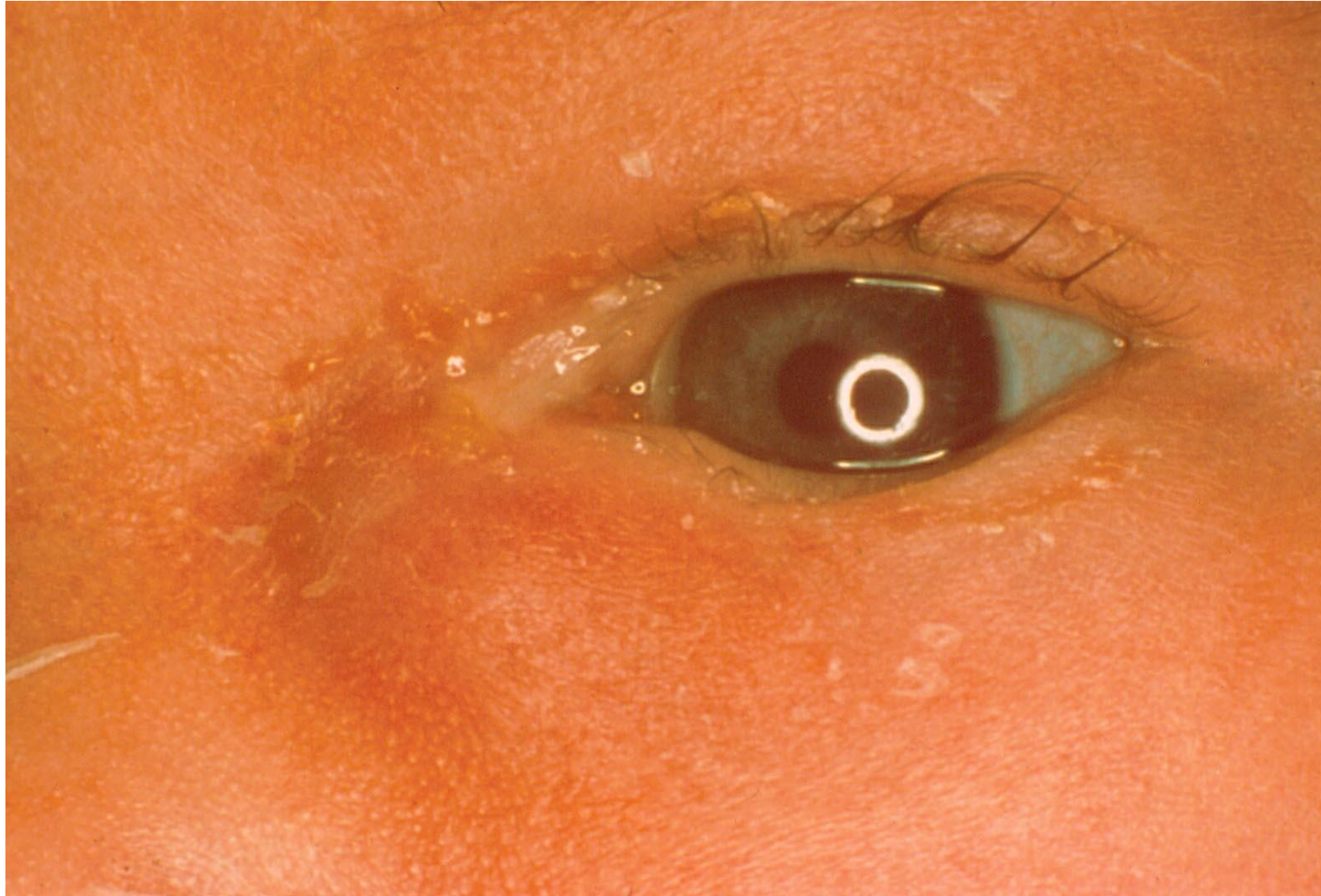




# Conjunctivitis



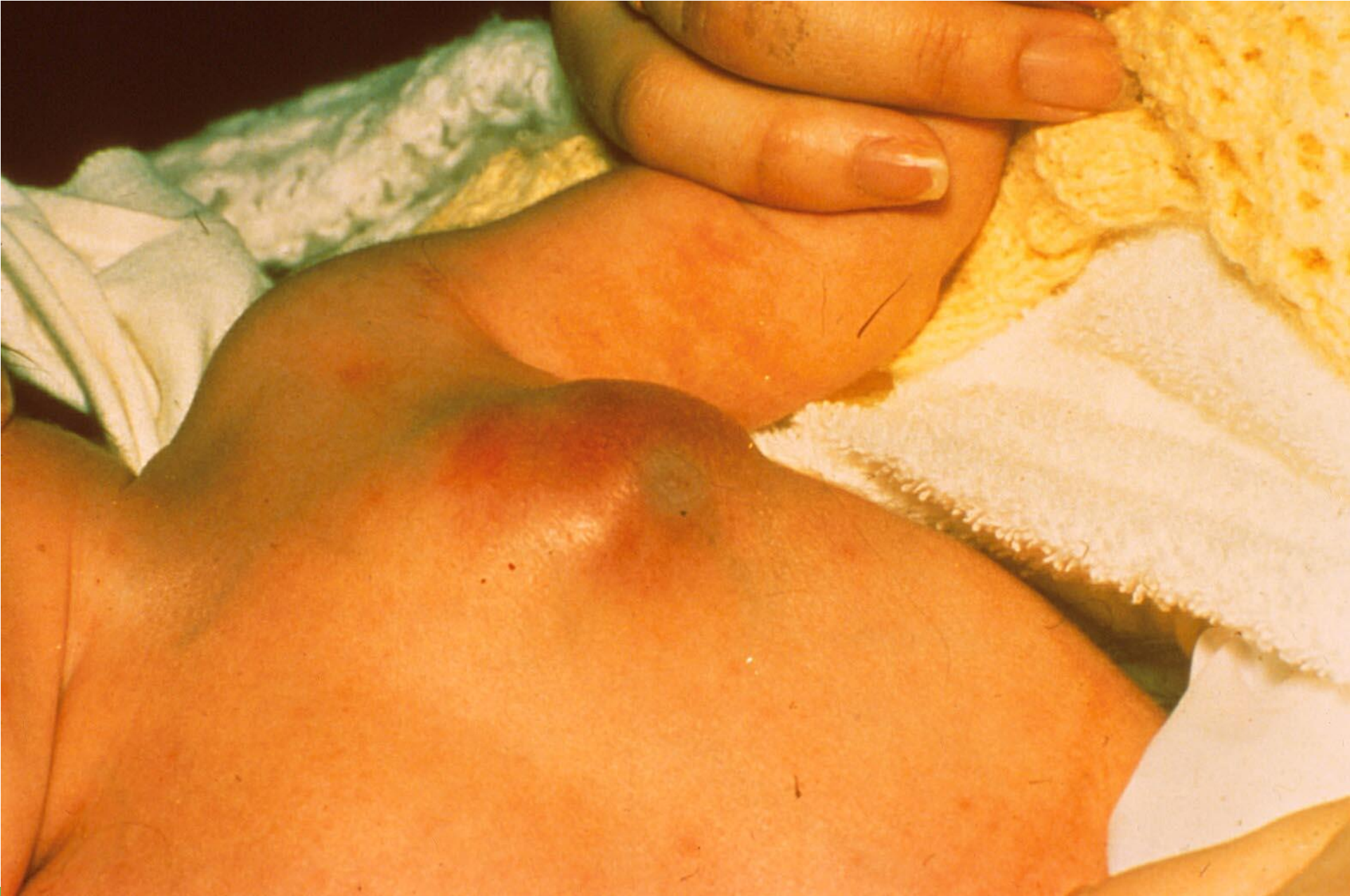# Dacryocystitis



# SKOÐUN NÝBURA

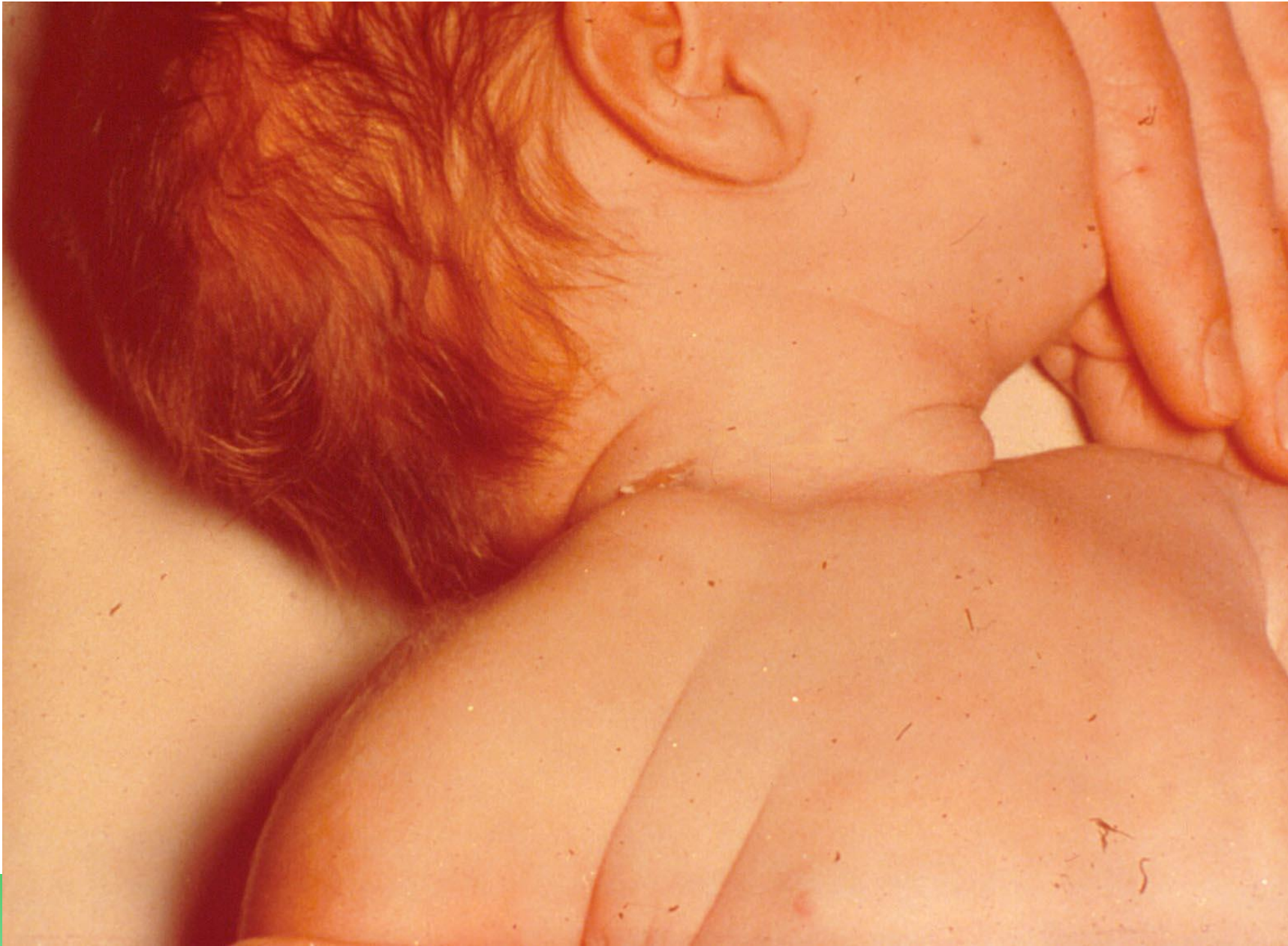
- Brjóstkassi / Lungu
  - Öndunartíðni
  - Inndrættir, nasavængjablakt
  - Lungnahlustun
- Hjarta- og æðakerfi
  - Hjartahlustun
  - Femoral púlsar

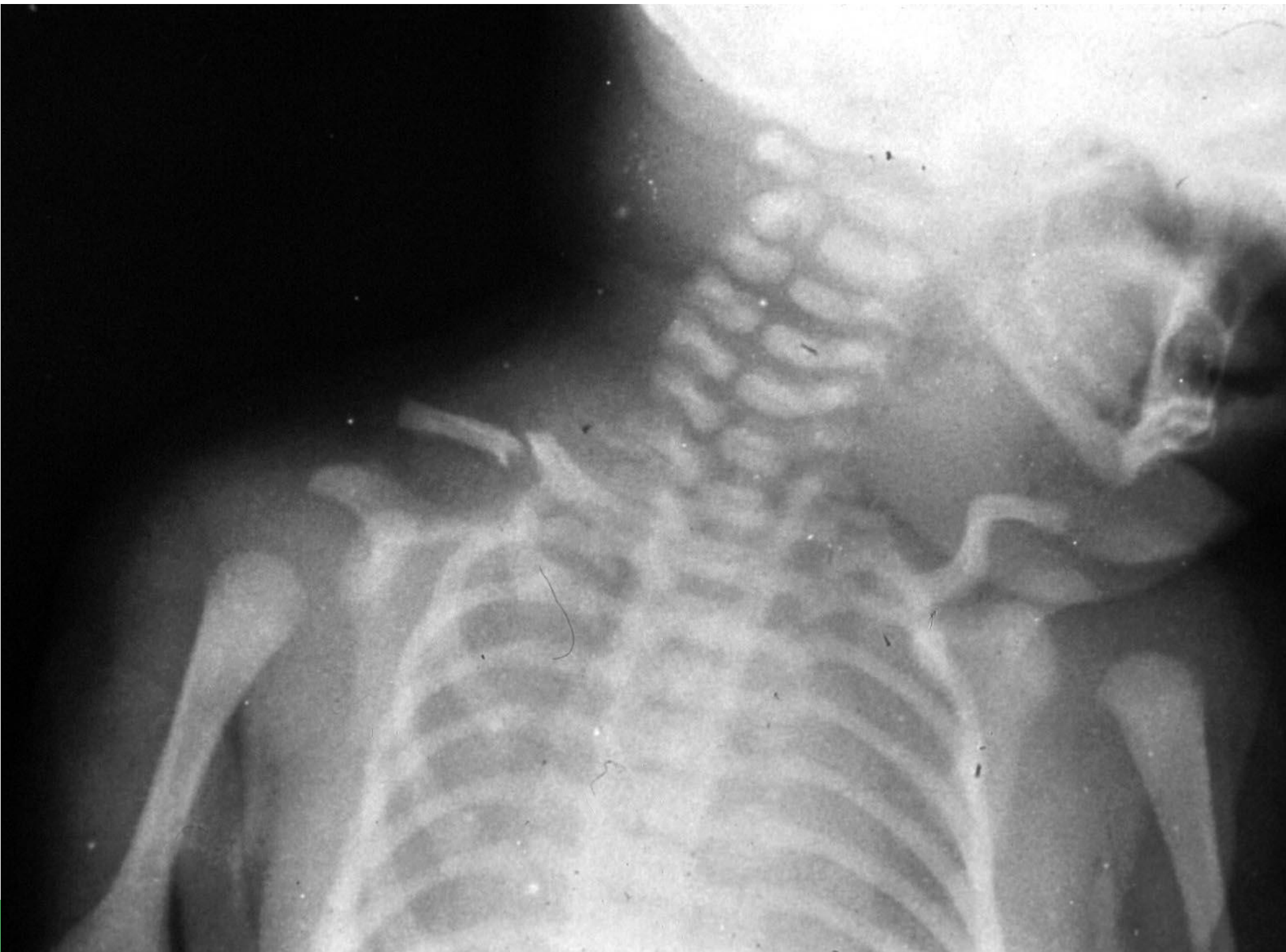





# Viðbeinsbrot



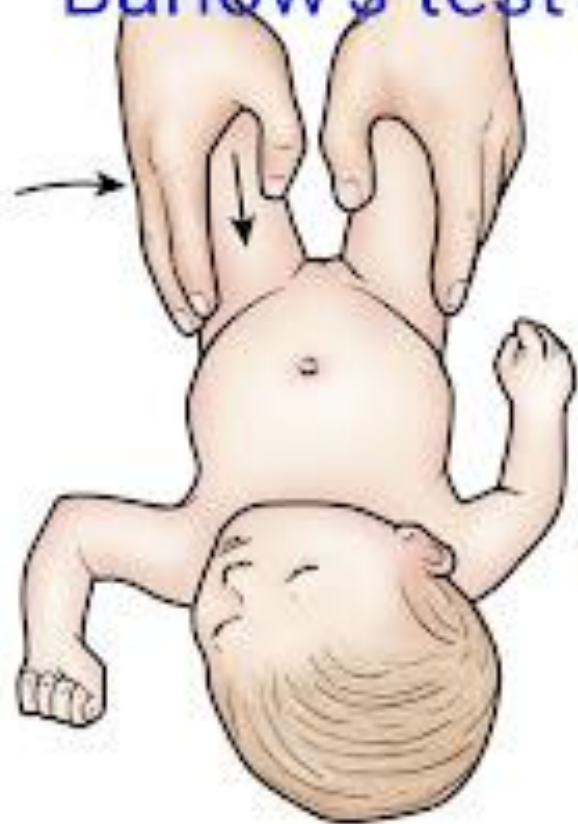

# SKOÐUN NÝBURA

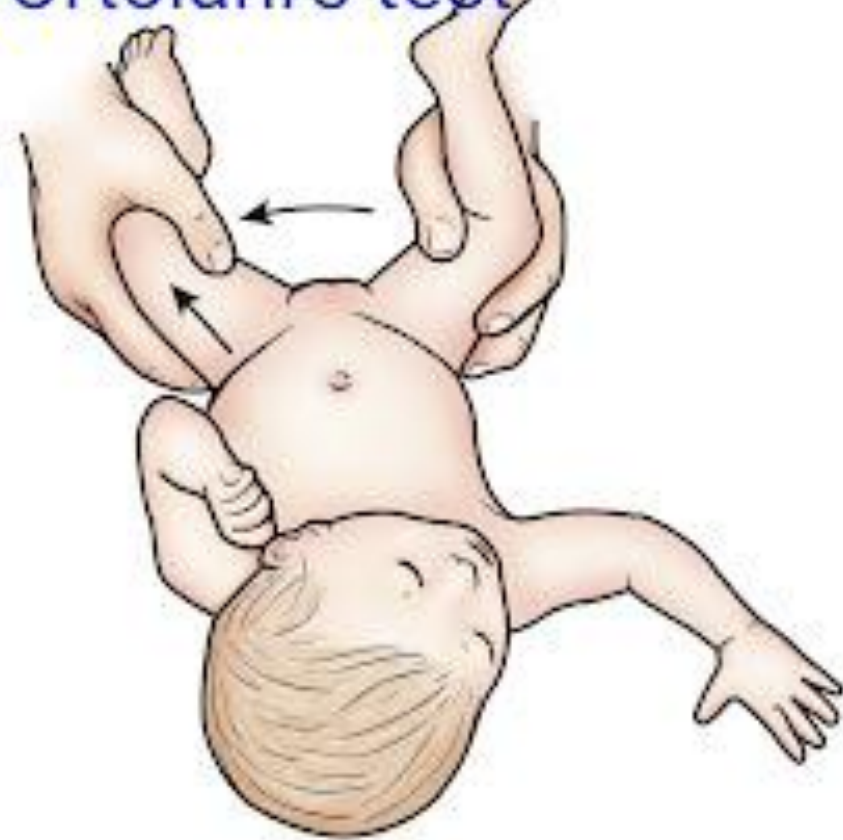- Kviður
  - Líffærastækkanir (lifur, milta, nýru)
  - Fyrirferðir
- Endaþarmur
- Ytri kynfæri
- Mjaðmir og útlimir
  - Ortholani og Barlow próf



Barlow's test

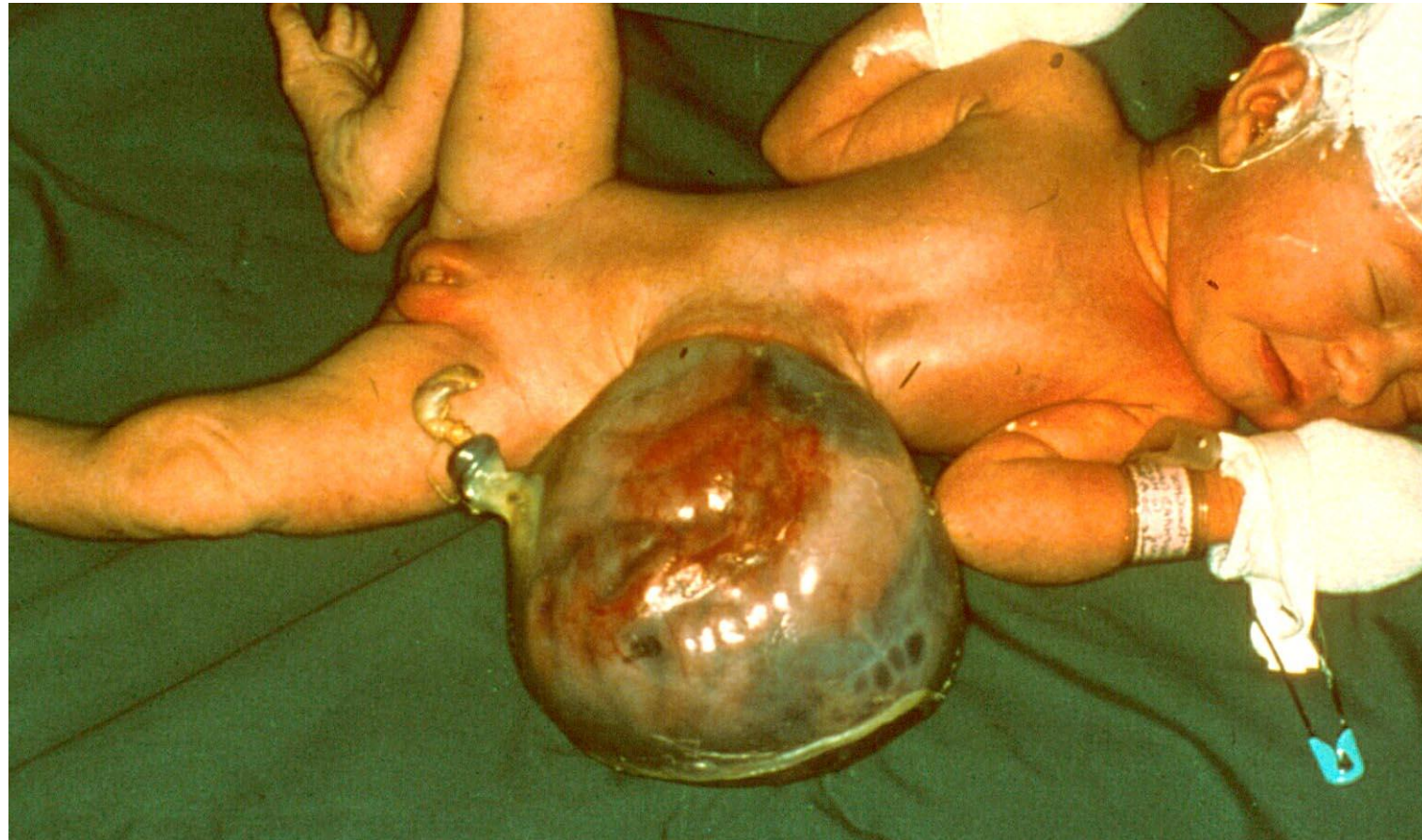

Ortolani's test

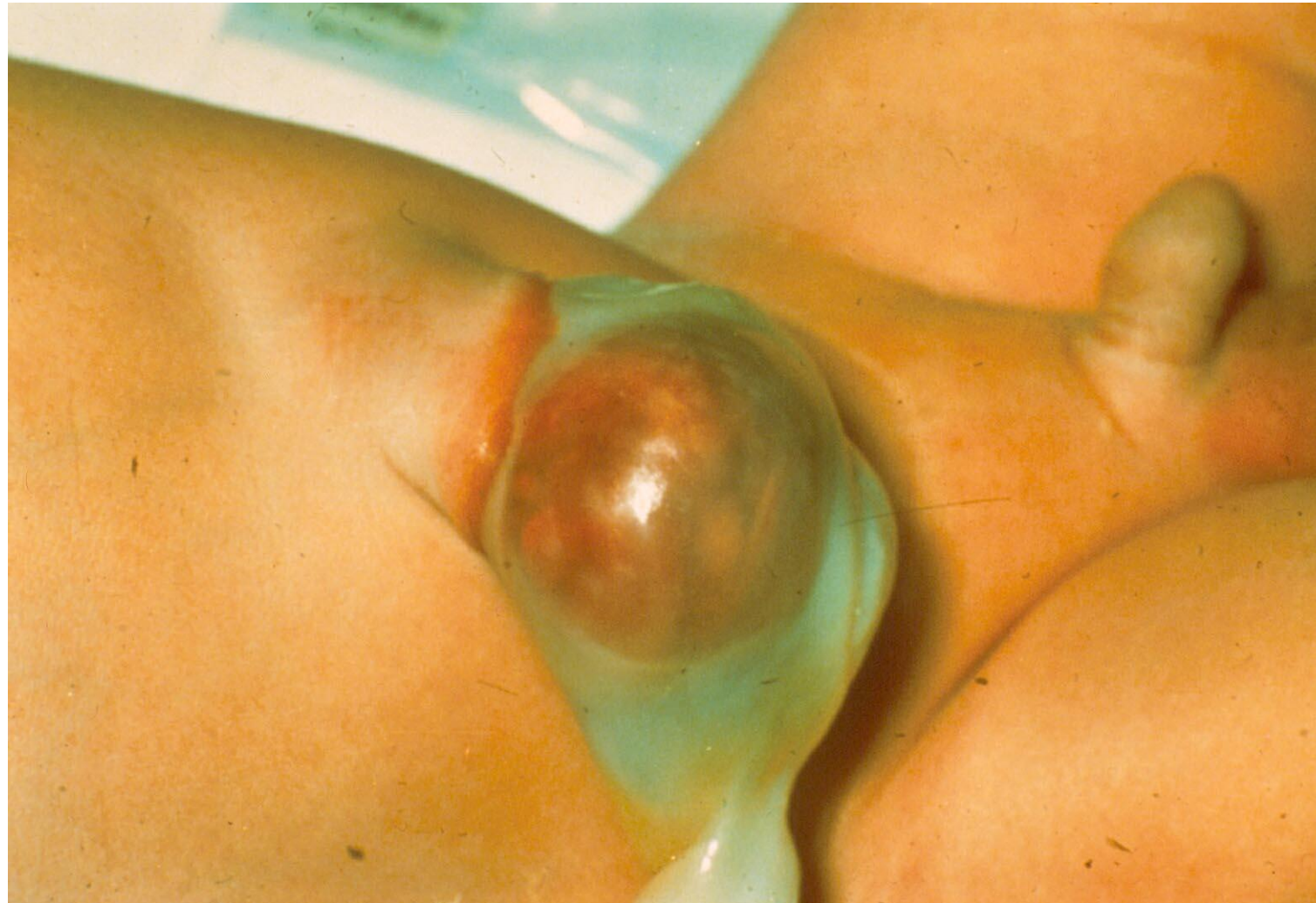



# Omphalocele

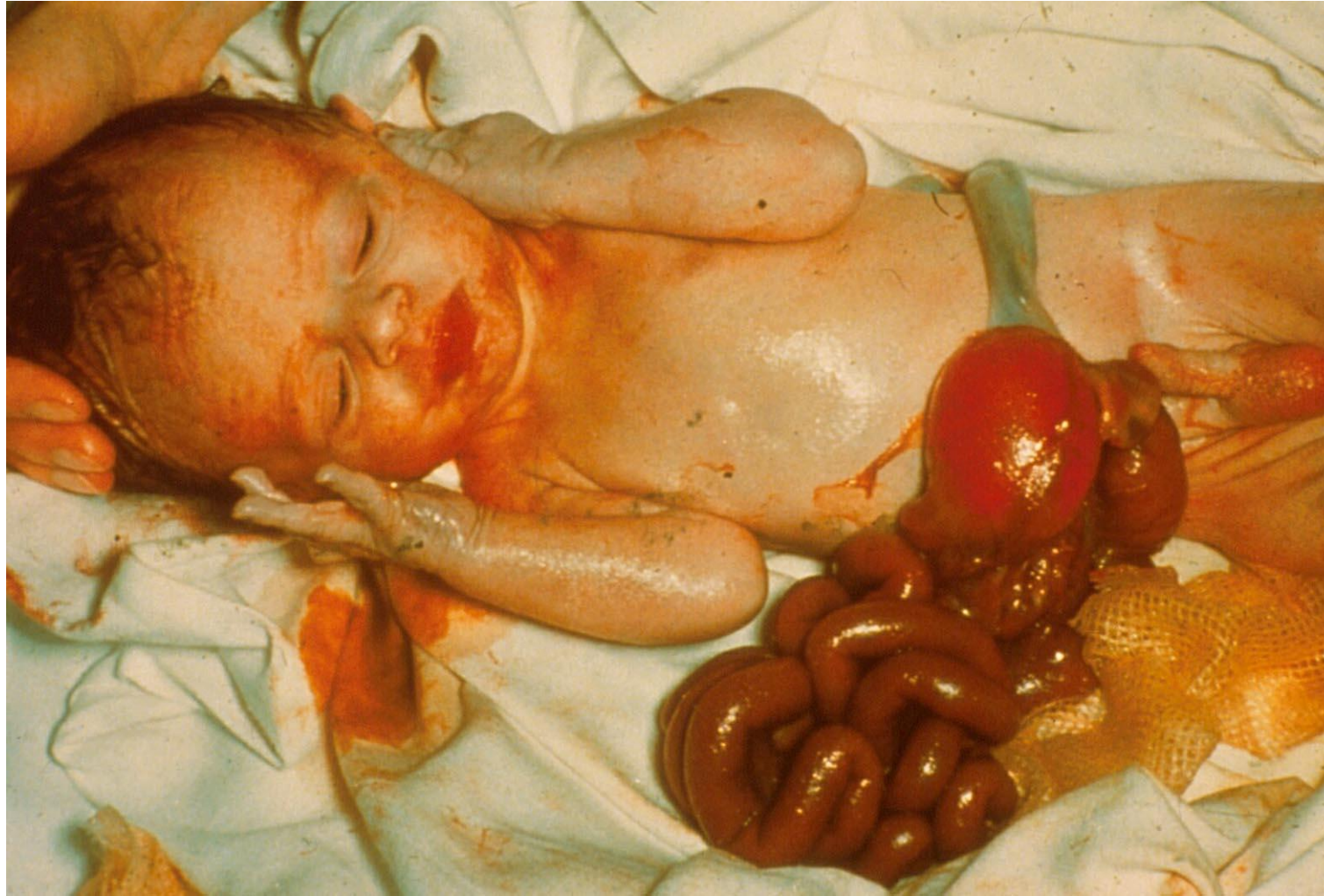

# Omphalocele

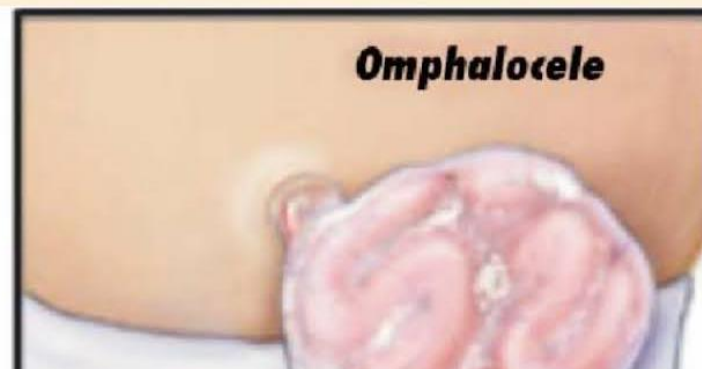
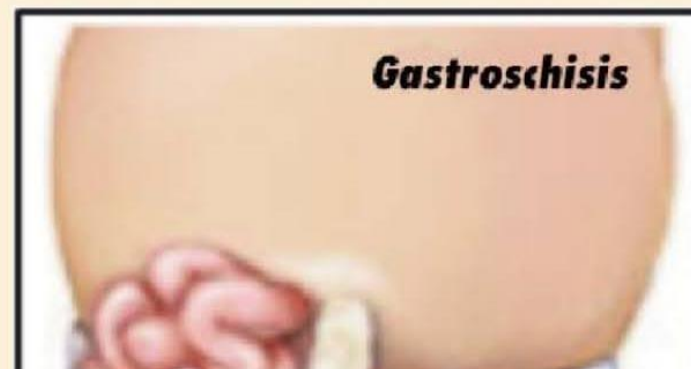



# Gastroschisis

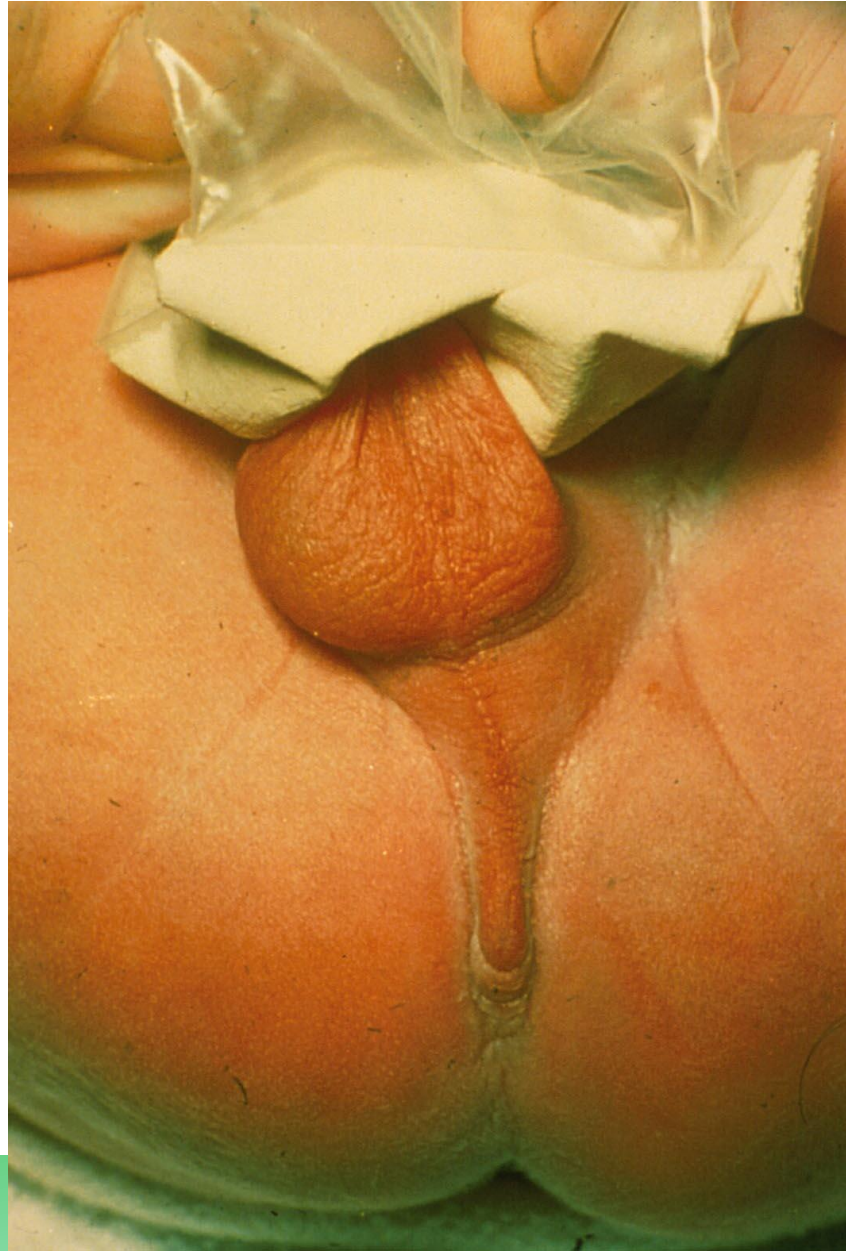

Defect size (diameter)	2–3 cm	2–15 cm
Sac	Never	Always, may be ruptured
Gestational age	Prematurity	Term
Umbilical cord	Adjacent (left side) of defect	Attached to sac
Herniated viscera	Small bowel, stomach, colon	Small bowel, stomach, colon, liver
Malrotation	Yes	Yes
Bowel character	Inflammatory, edematous	Normal
Enteral nutrition	Delayed	Normal
Associated anomalies	Uncommon (10% atresia)	Common (50%)

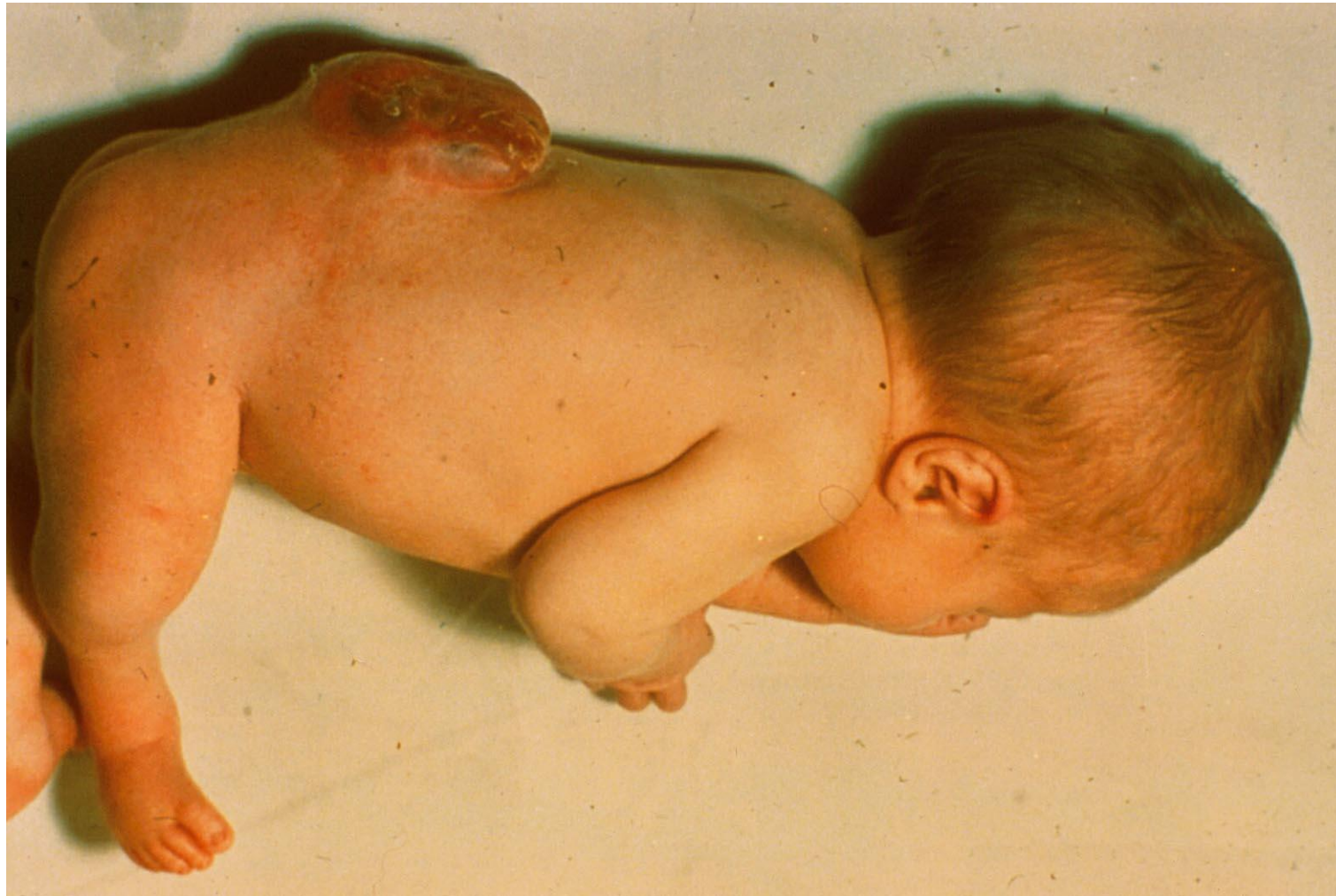


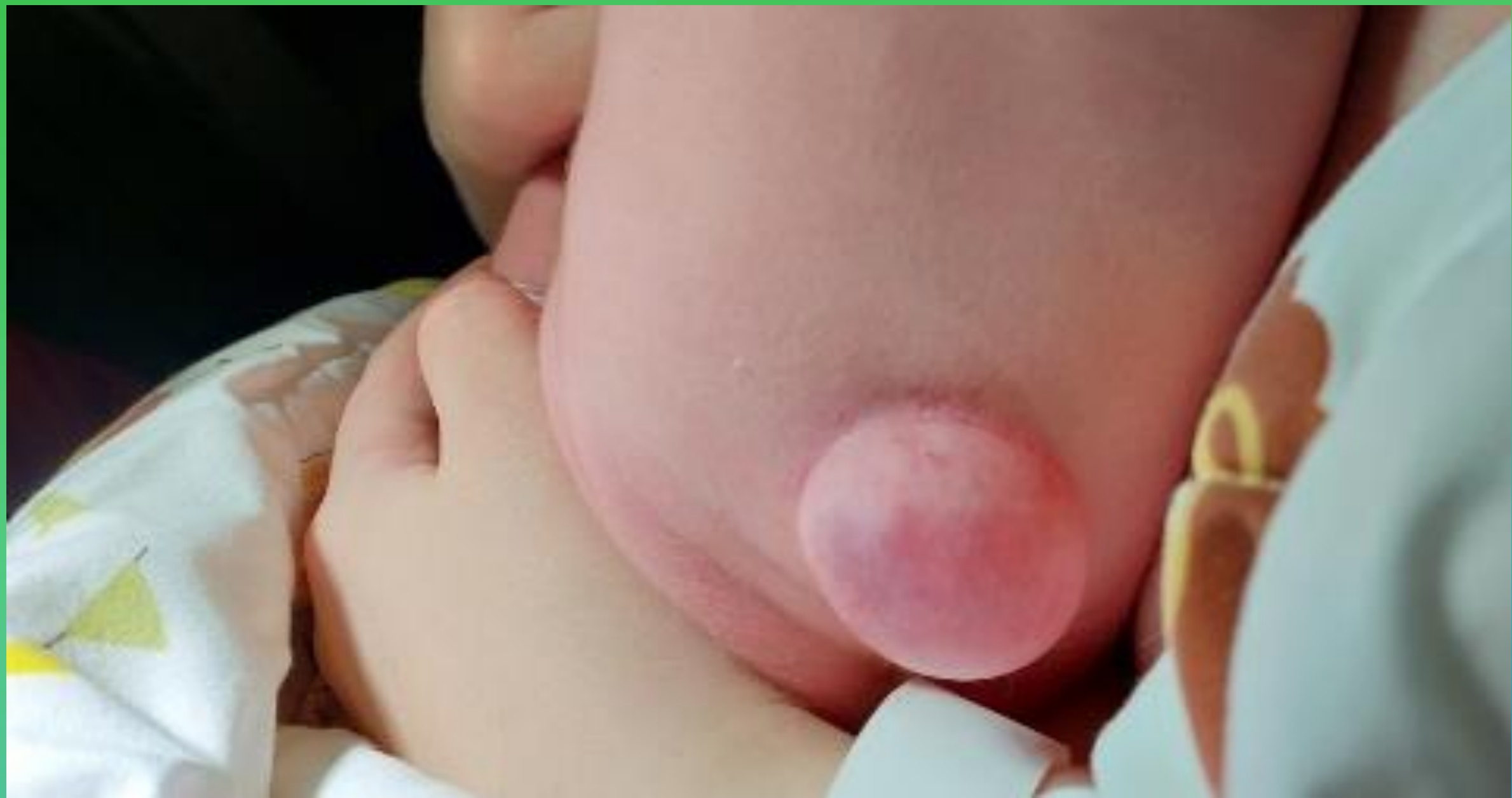
# Imperforate anus



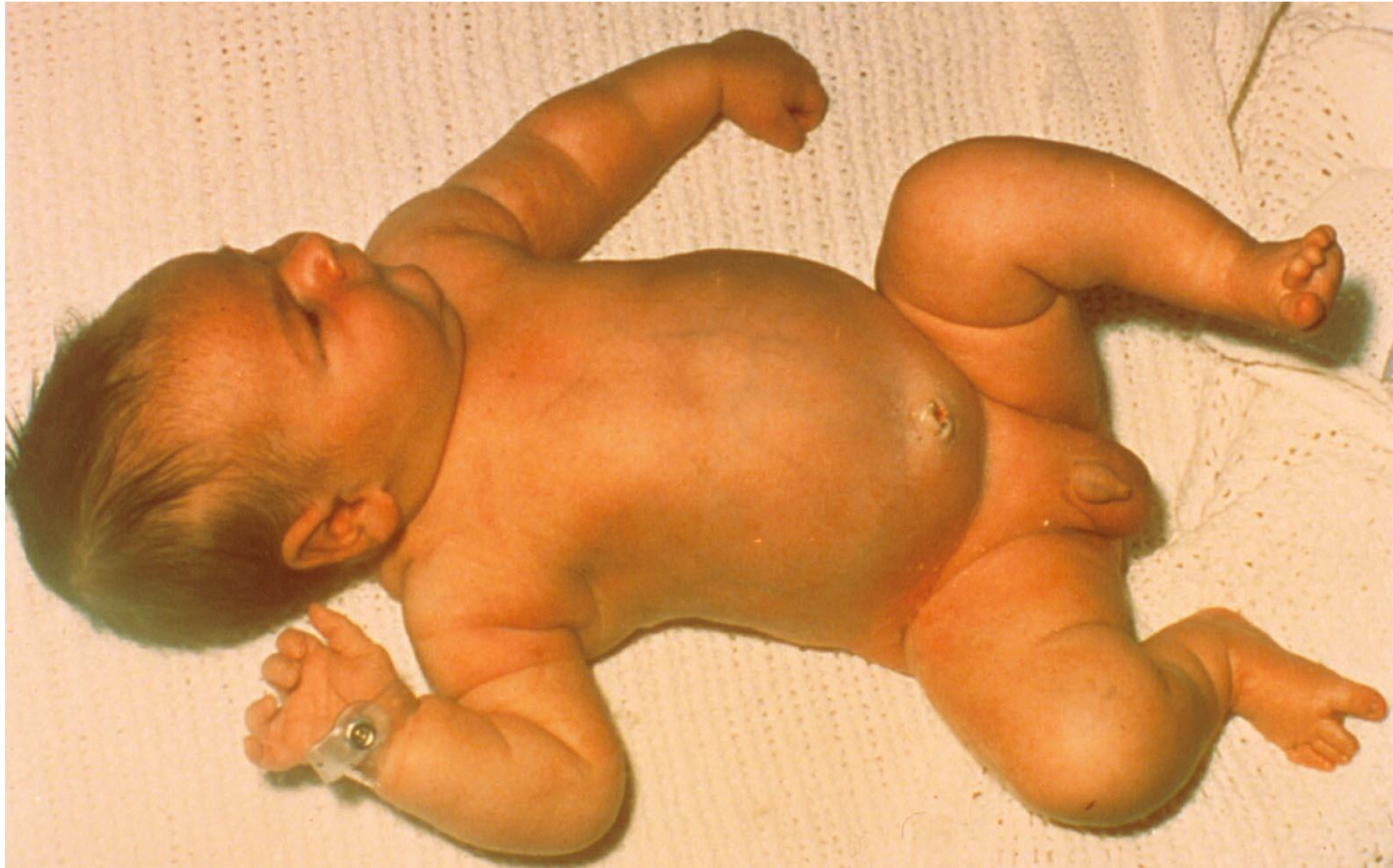# Spina bifida



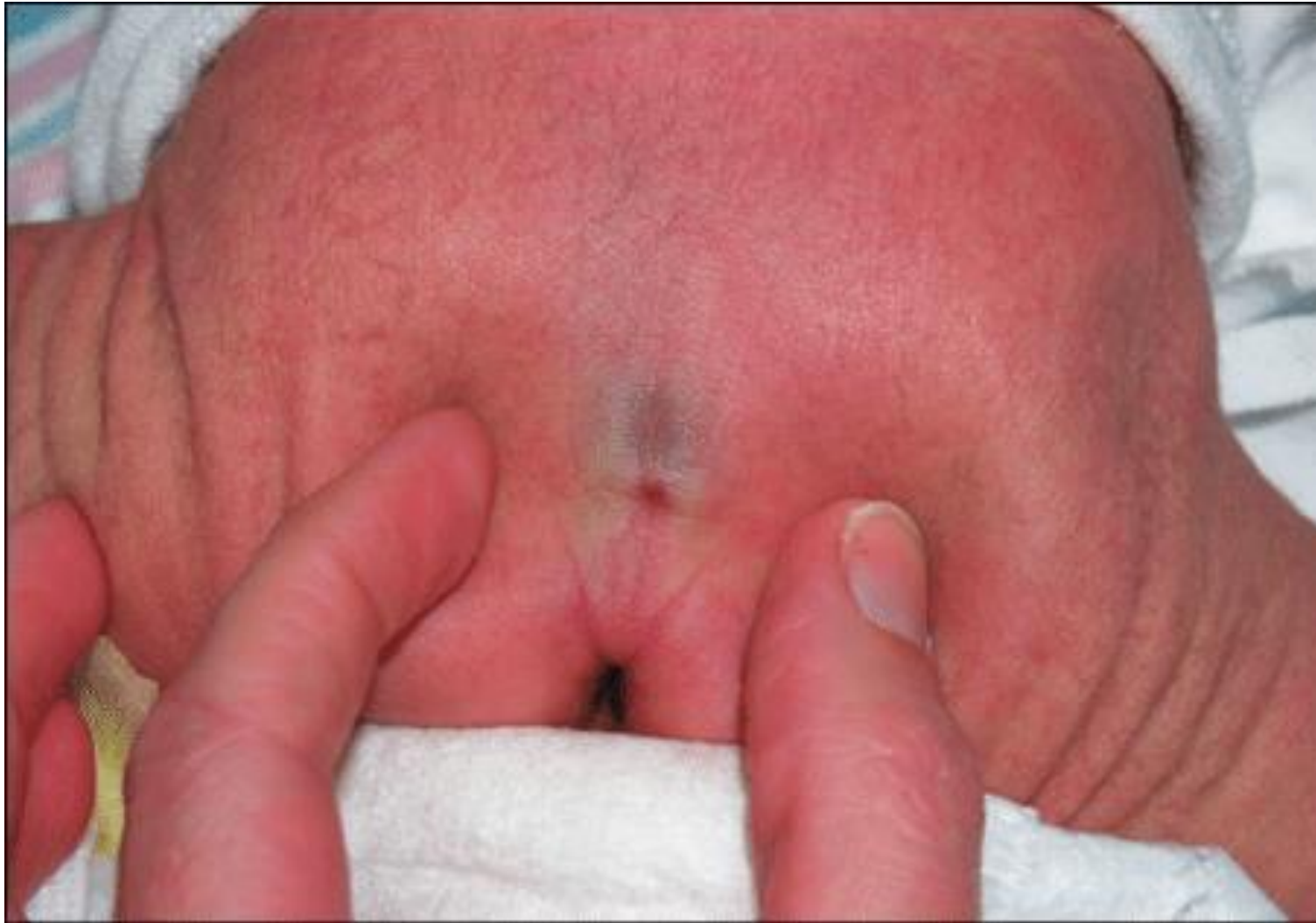



## Erb's paresis af völdum axlarklemmu







	<b>Simple dimple</b>	<b>Sinister dimple</b>
Location	Within natal cleft Within 2.5 cms of anal orifice	Above natal cleft
Appearance	Superficial Floor of the dimple can be seen No discolouration No tuft of hair No drainage No fibrous connection or stalk Fibrous stalk directed towards coccyx tip	Deep No floor seen (?) Discolouration of skin, strawberry angioma Tuft of hair Fluid drainage or debris Fibrous stalk directed cranially
Family history	None	Previous dimples, Spina bifida, Neural tube defects

# FIMM DAGA SKOÐUN

- Þyngd
  - Þyngdartap?
- Gula?
- Sýkingar í húð?
- Nýtilkomin hjartaóhljóð?
- Femoral púlsar?



# NÝBURASKIMUN

- Blóðprufa tekin 48-72 klst e fæðingu
- Skimað fyrir
  - Vanstarfsemi skjaldkirtils (TSH mælt)
  - Vanstarfsemi nýrnahettna
  - PKU (Phenylketonuria)
  - Öðrum sjaldgæfari efnaskiptasjúkdómum

# FYRIRBURI

Barn sem fæðist fyrir 37 vikna meðgöngu

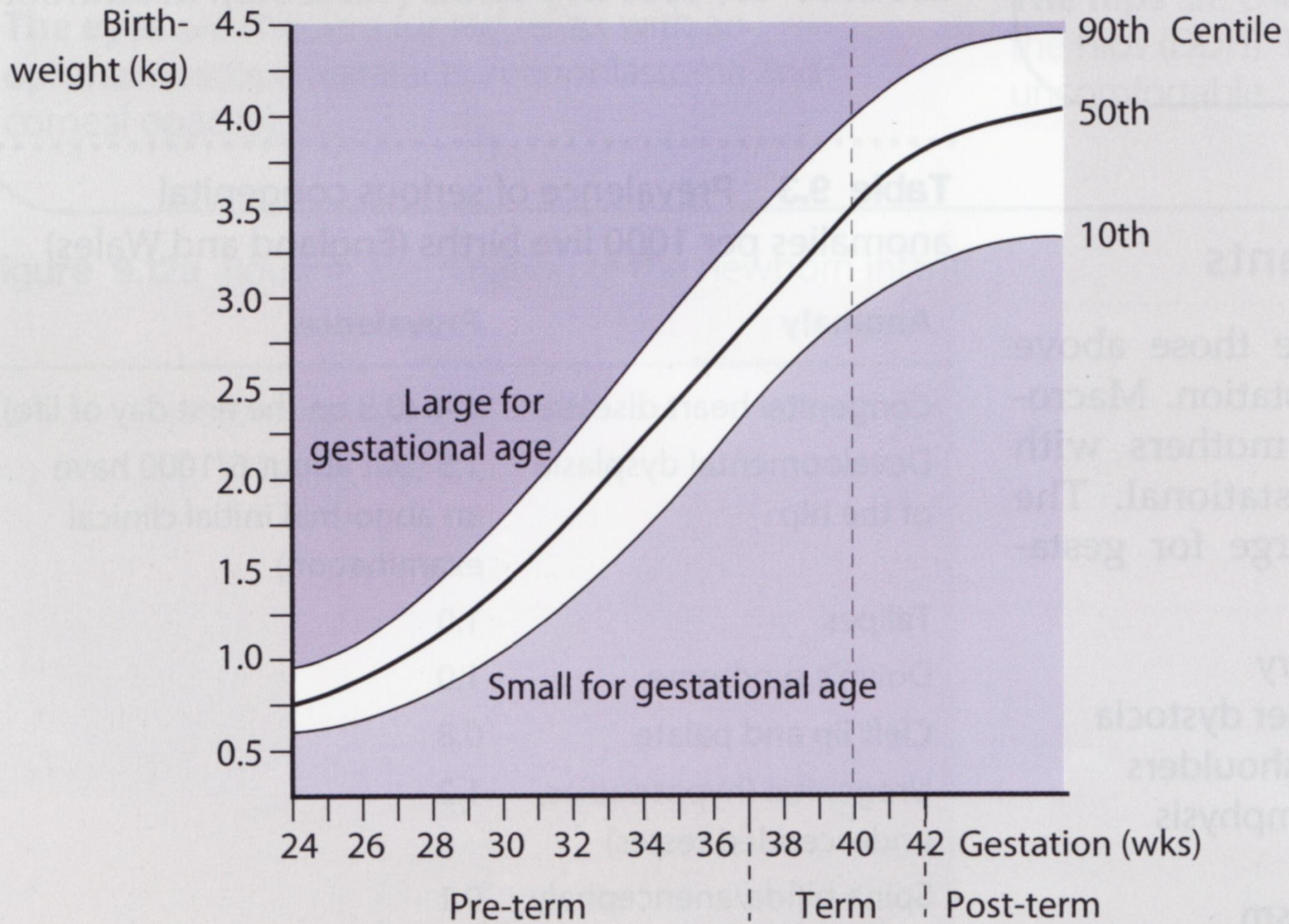
# LÁG FÆÐINGARÞYNGD

Barn sem er < 2500 g við fæðingu

# LÉTTBURI

Barn sem er léttara  
en meðgöngulengd segir til um  
< 10% / < 2 staðalfrávik fyrir neðan meðalþyngd





Takk fyrir